



Complexity Made Simple

DR Amin Fouad
MD Cardiology

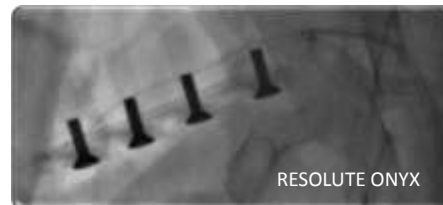
Resolute Onyx™

Superior Acute Performance combined with the Resolute drug coating

More Deliverable

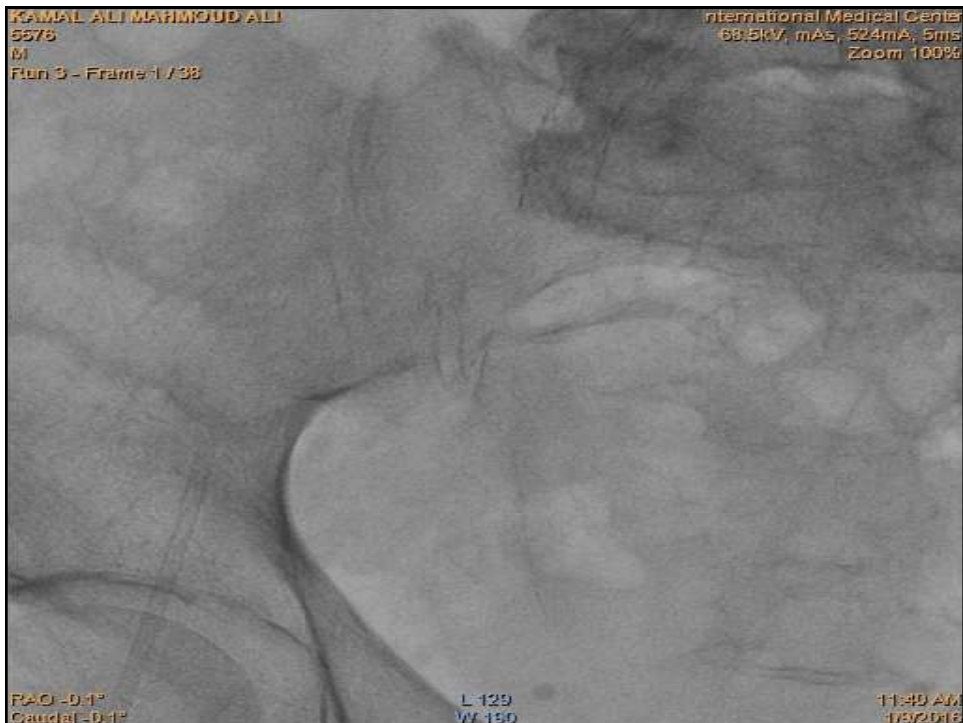

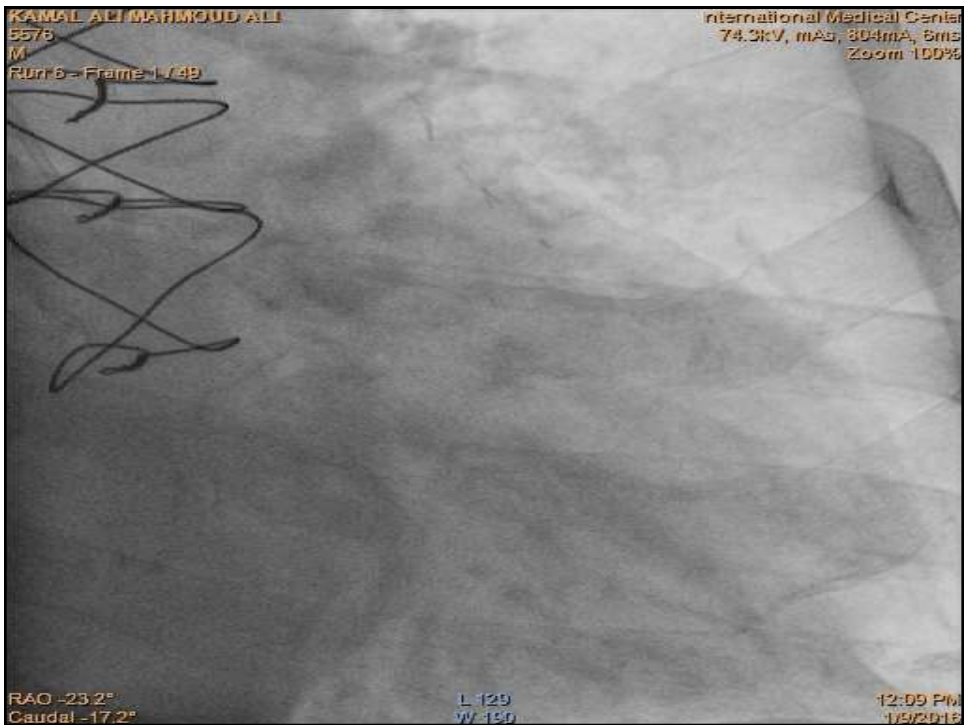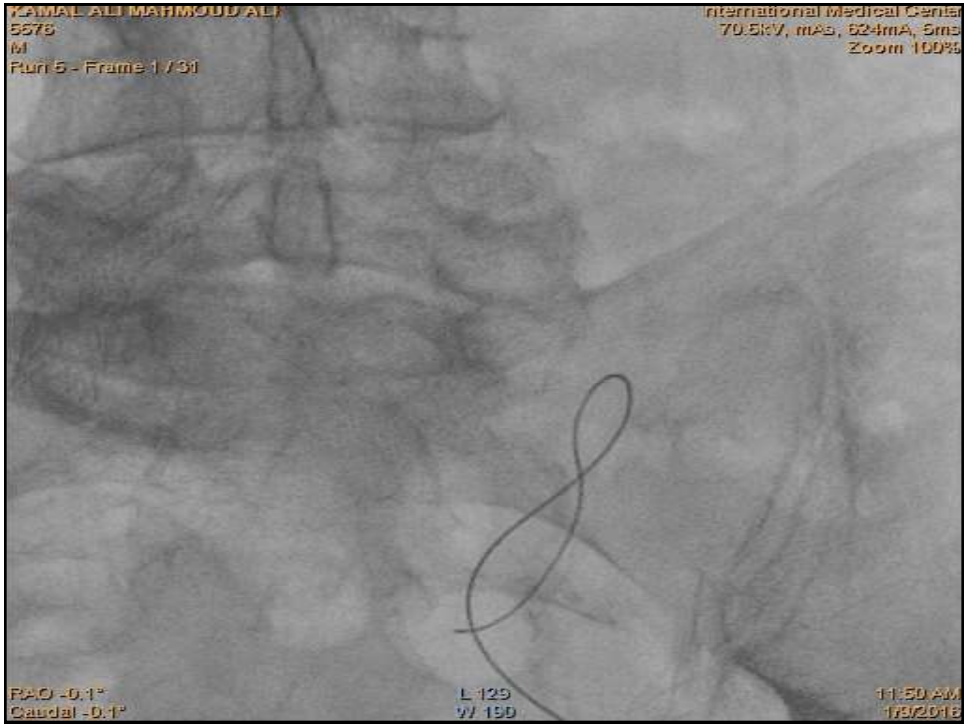
Promus Element Stent

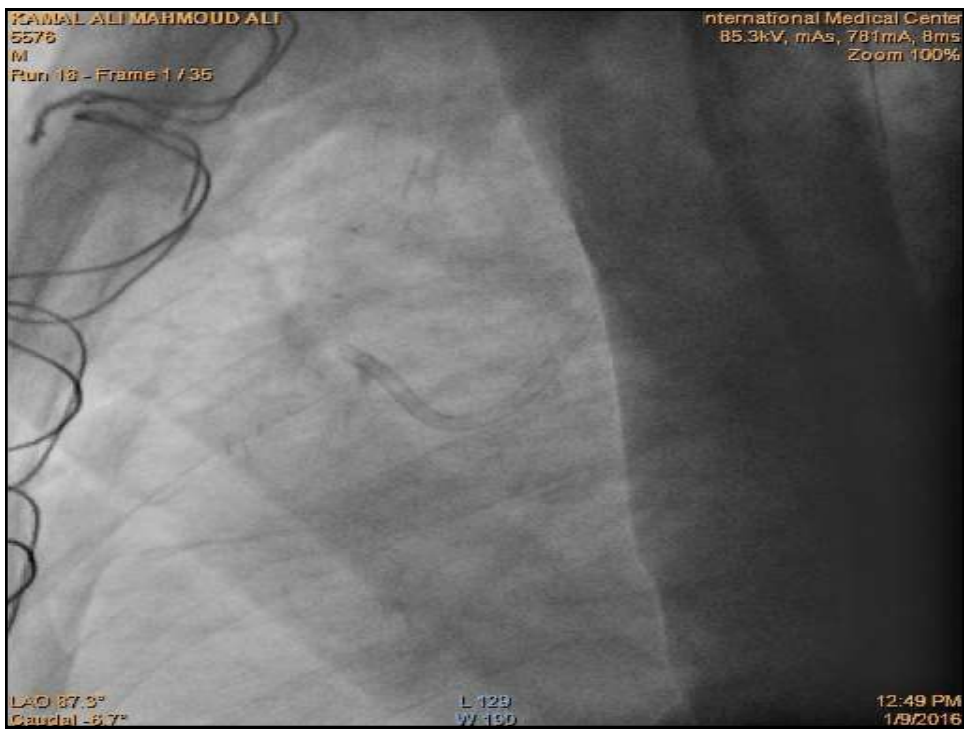
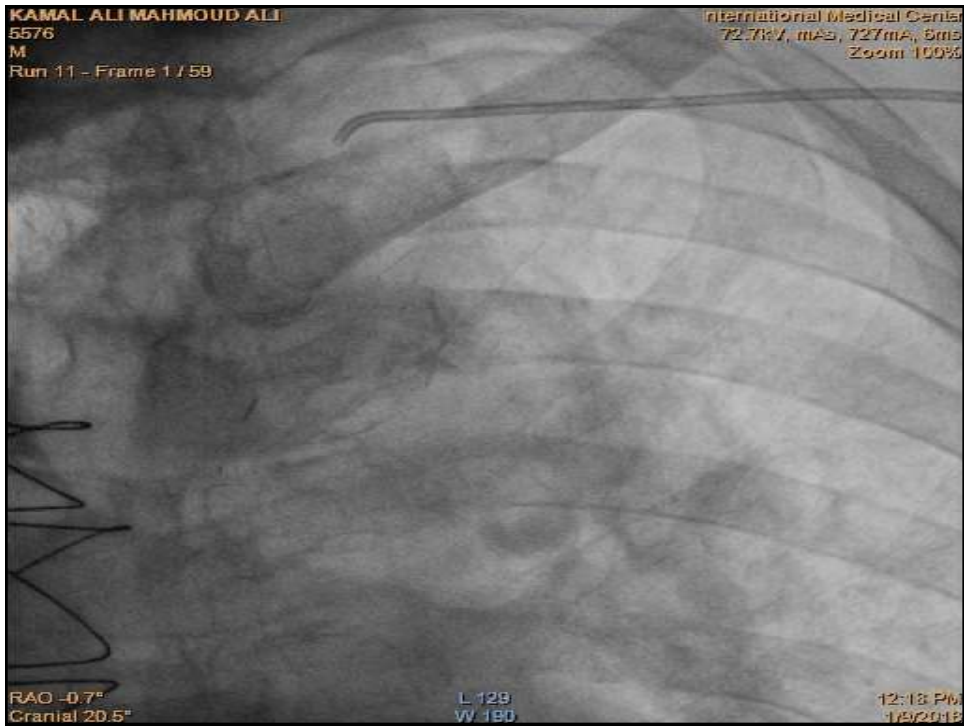

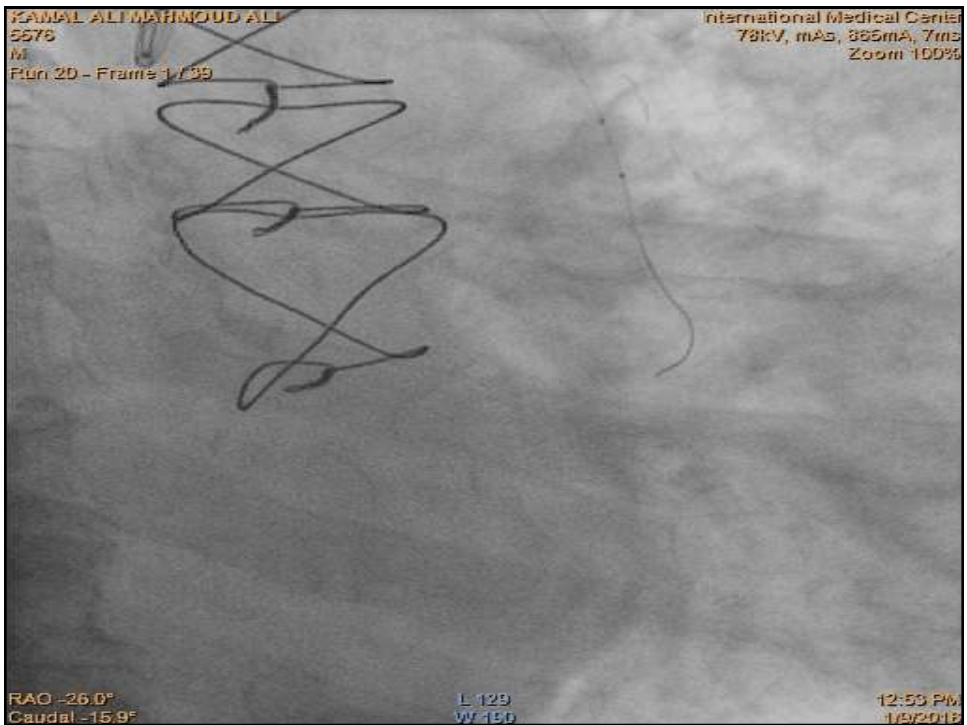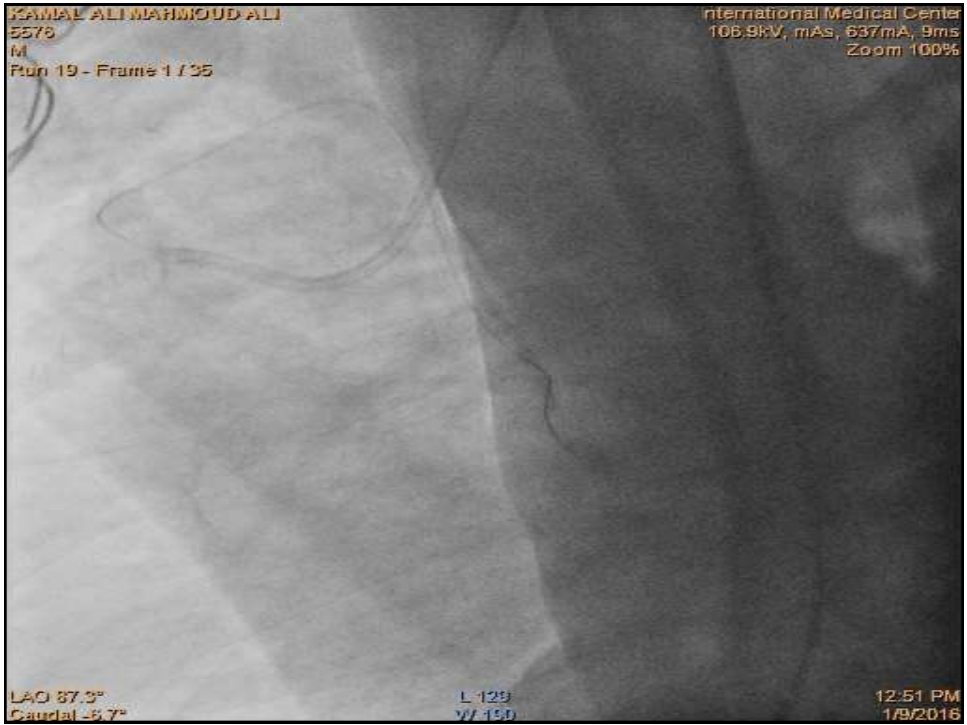
RESOLUTE ONYX

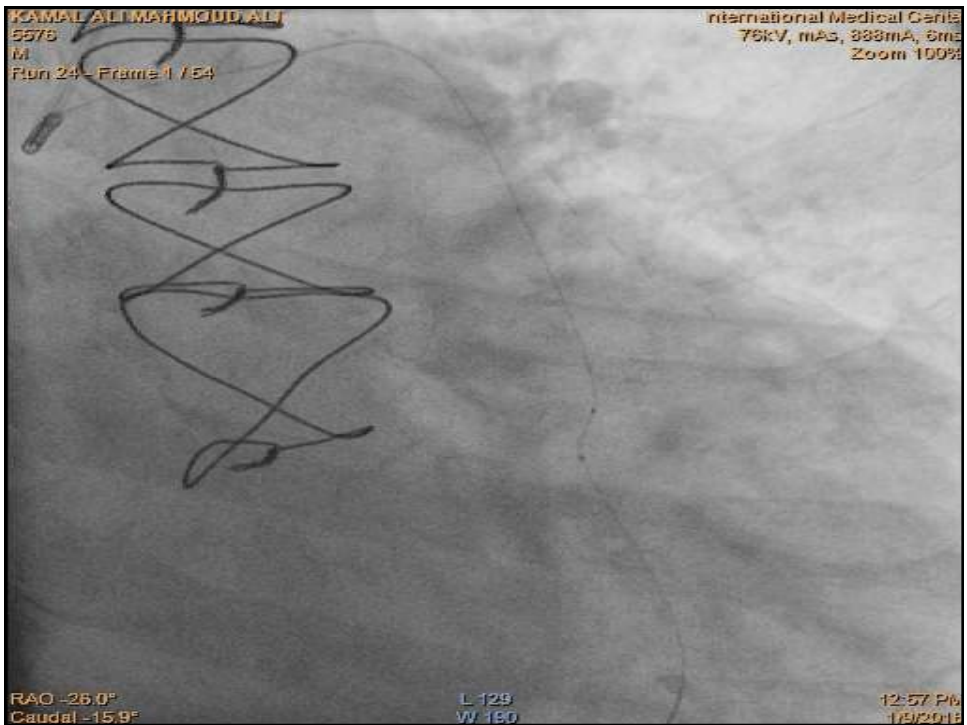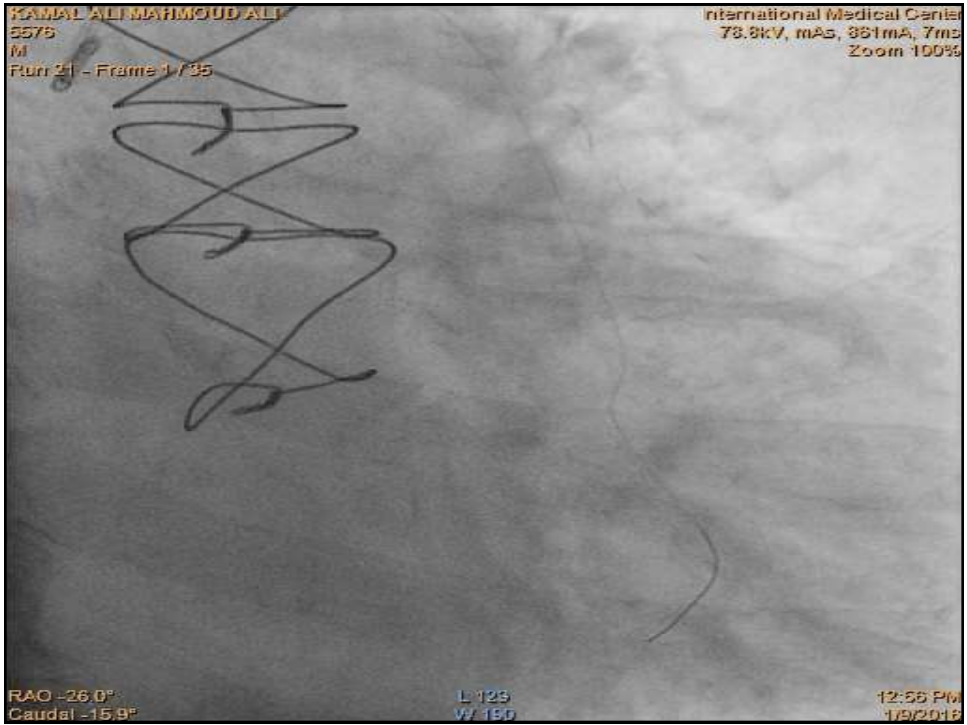- Mr KR is a 76y old pt .
- He is hypertensive , and diabetic (IDDM)
- He is ischemic heart dis since 20 years.
- He had CABG 12 years ago with LIMA to LAD, SVG to OM and, SVG to RCA.
- He has peripheral vascular dis. With RT common iliac stenting 4 years ago .
- He has renal impairment with S.Creat 3.4mg/dl .
- He has been admitted to our hospital with ACS and pul oedema .
- After medical stabilization and nephrological consultation CA was decided.

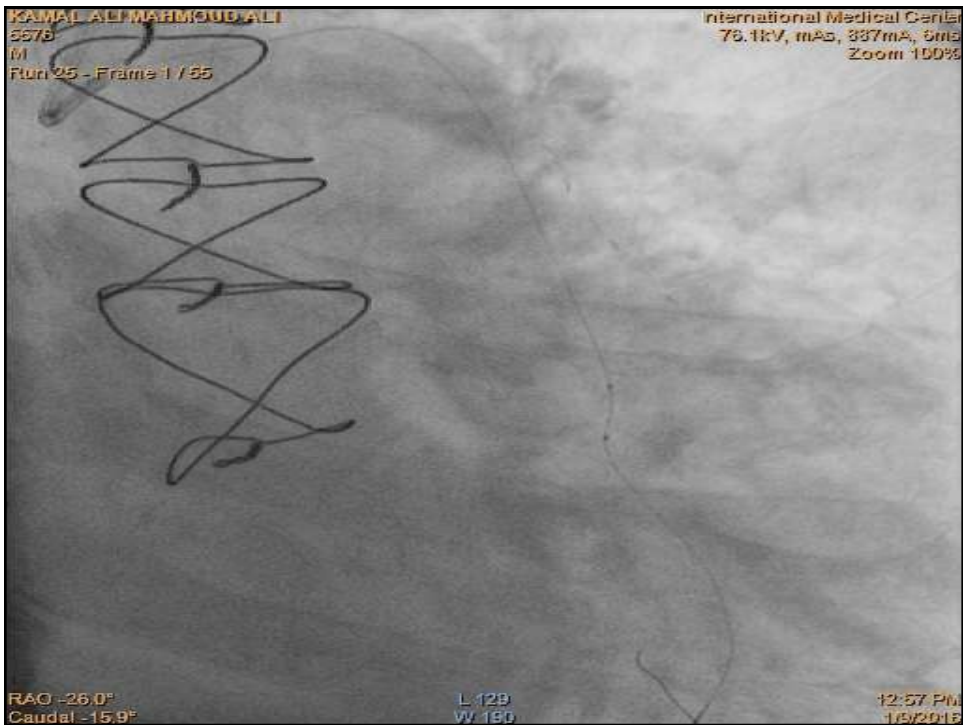
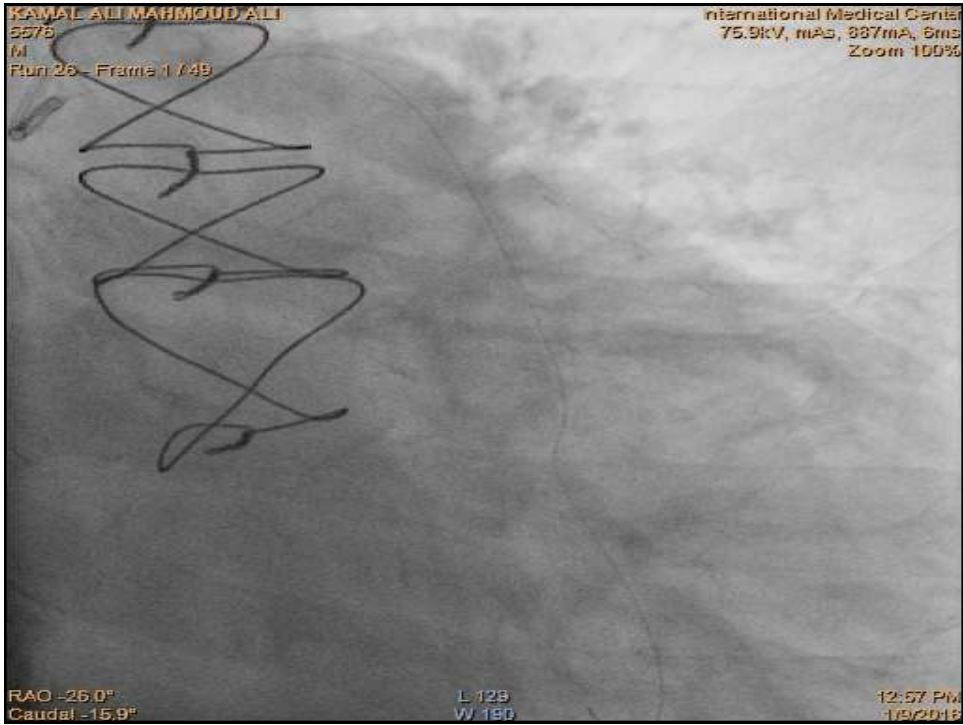
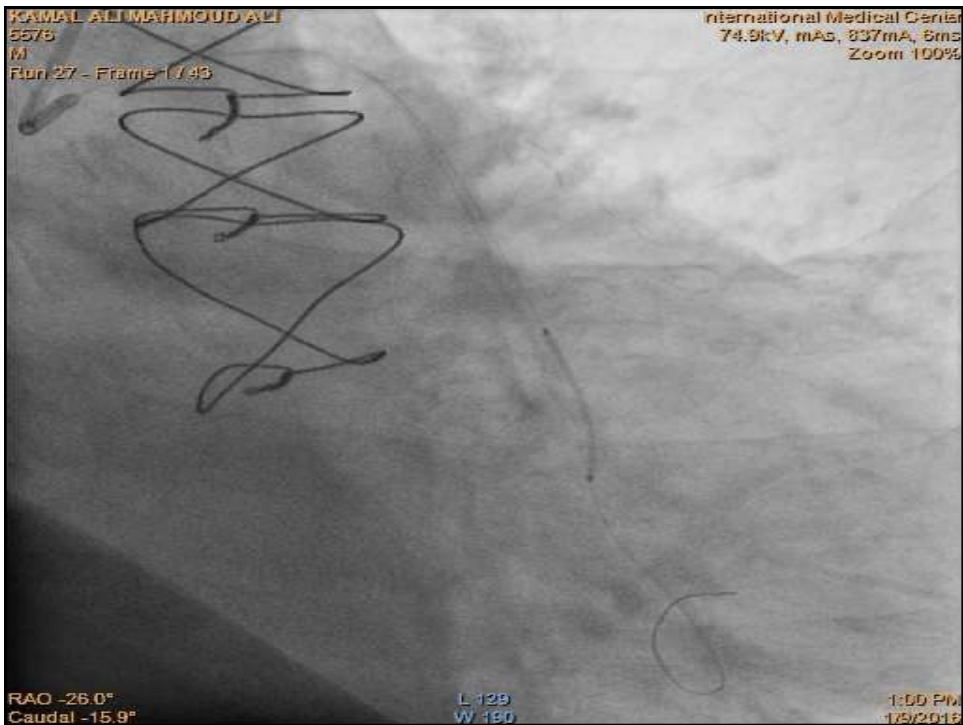


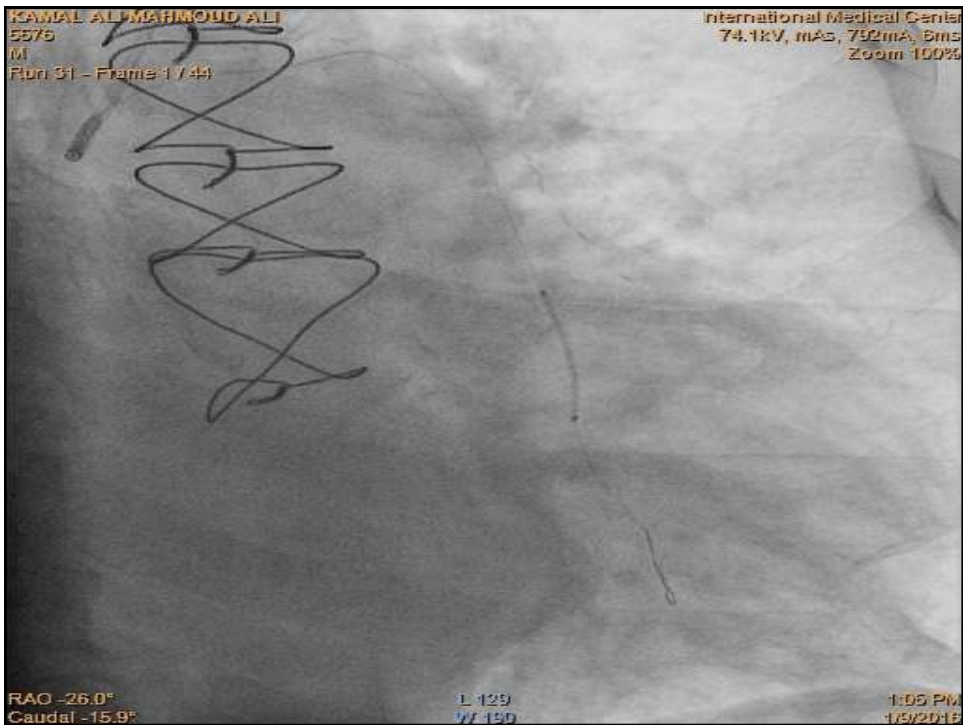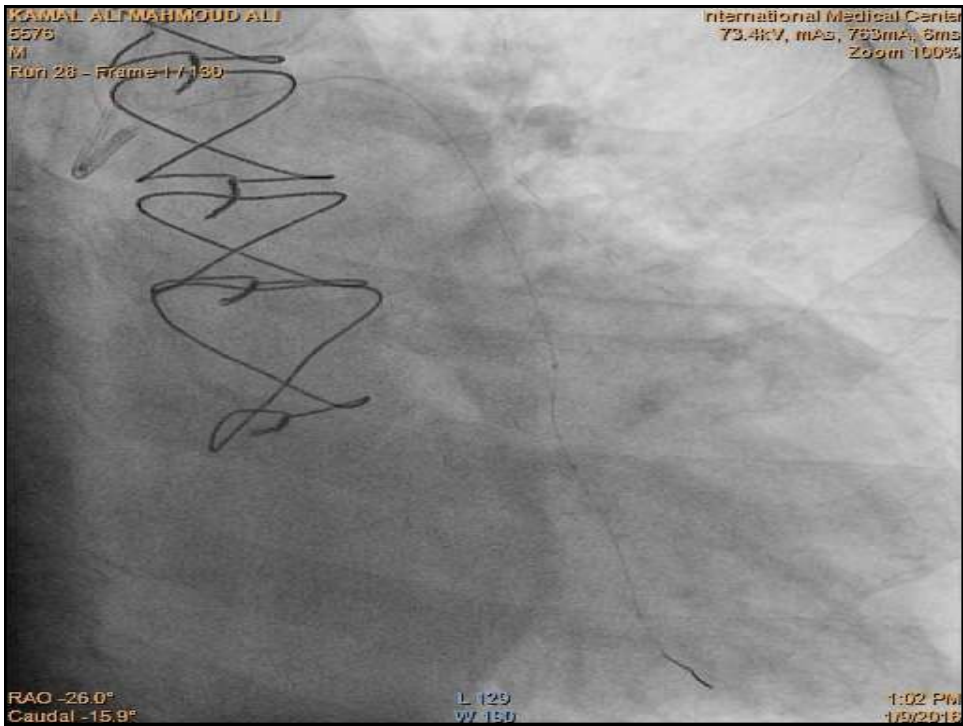






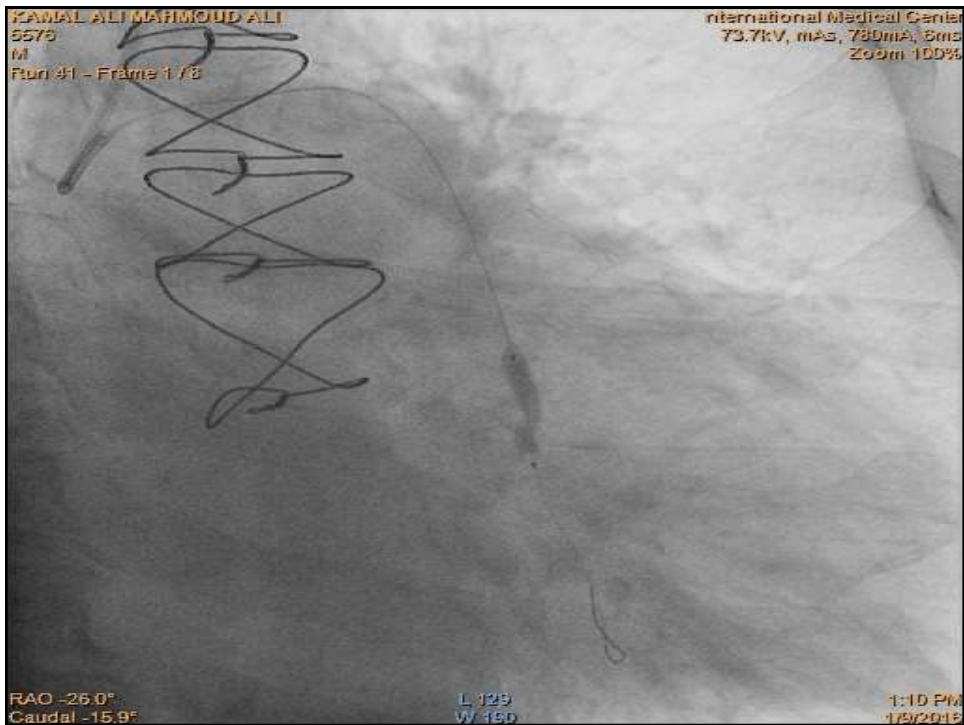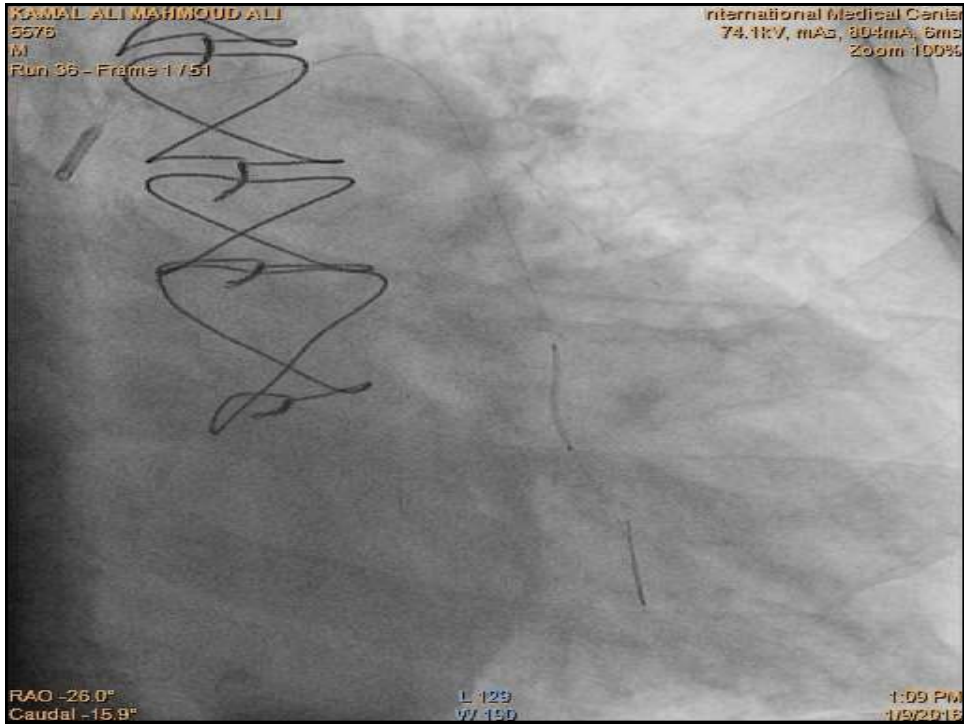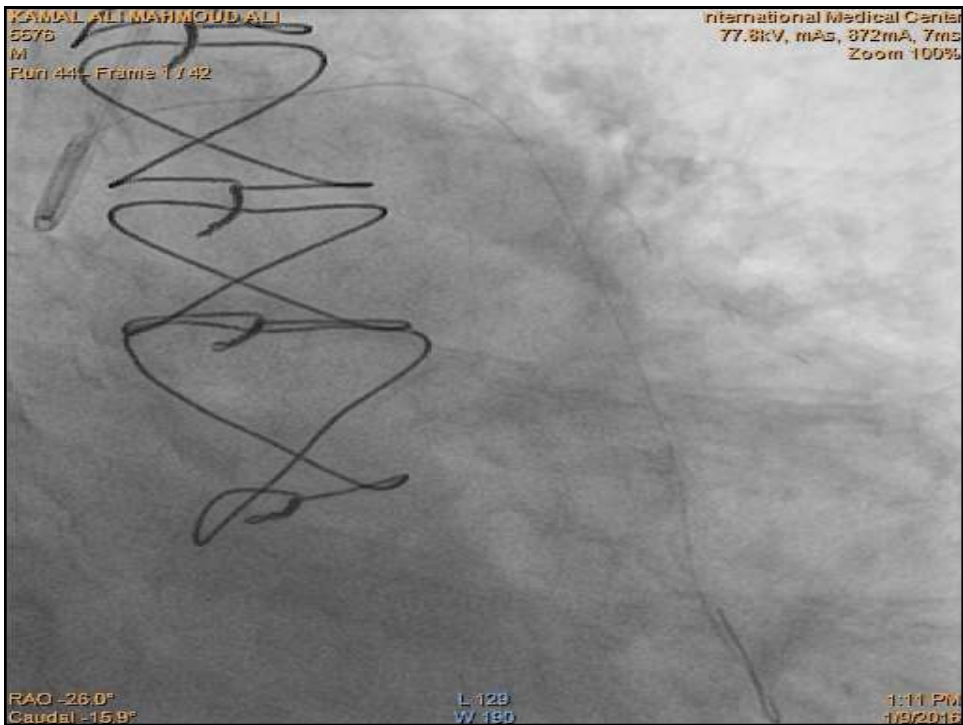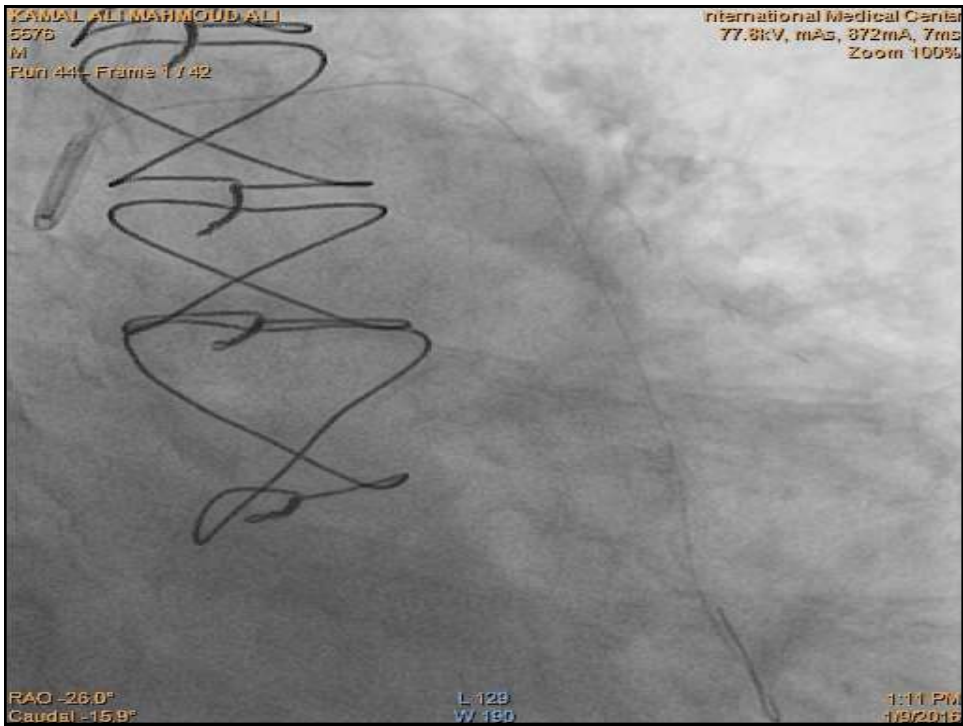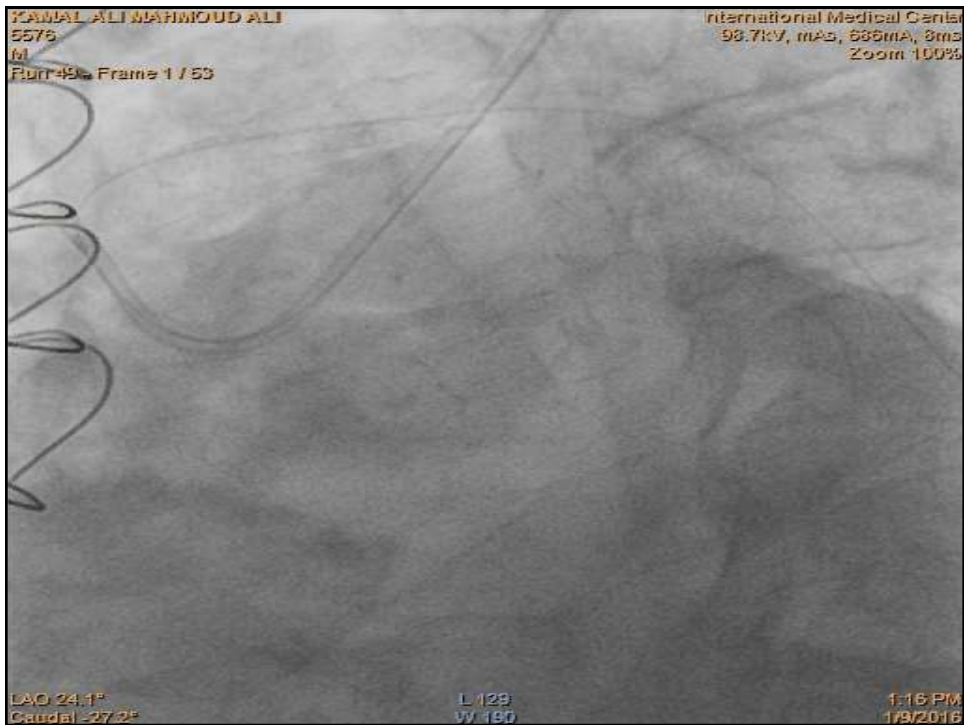
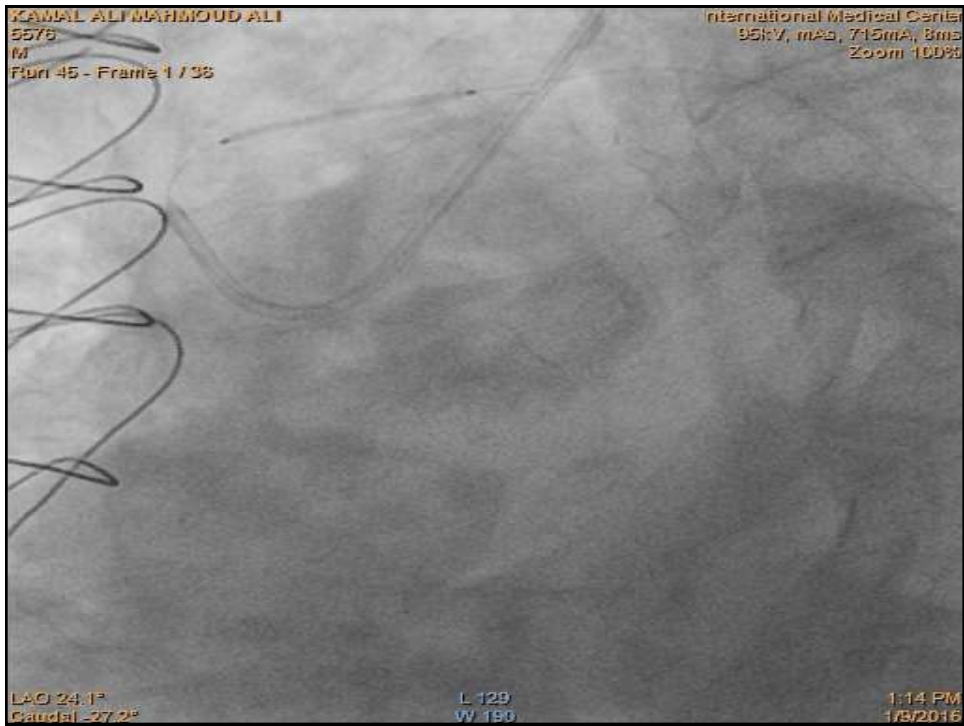










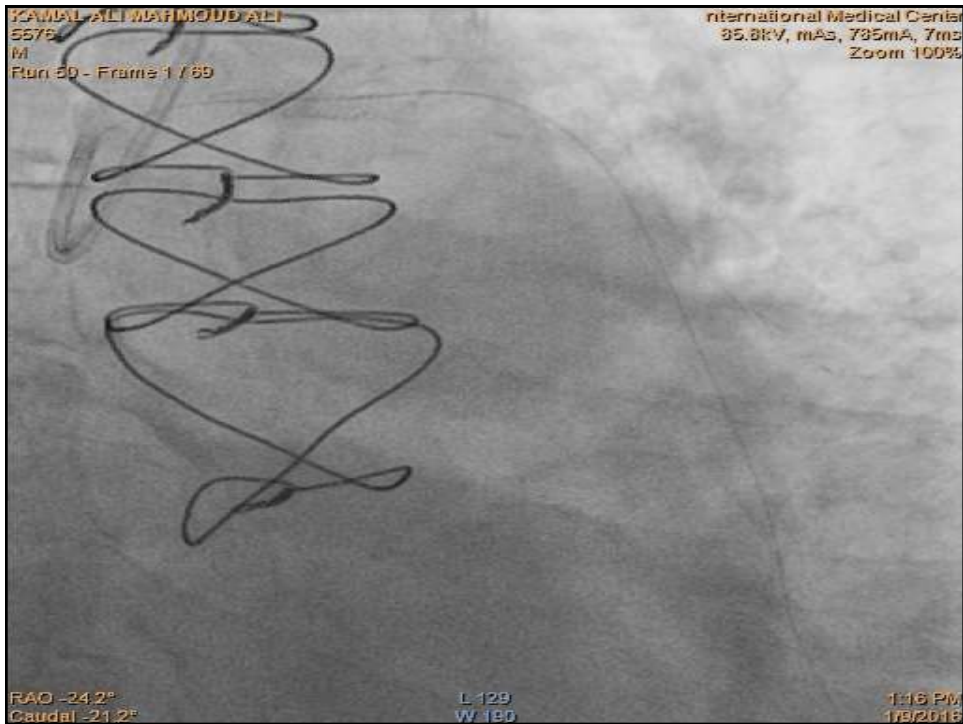



Take home message

- Stents should have a good balance between deliverability, pushability, and radial force.
- Some lesions need specific stents.

Thanks