


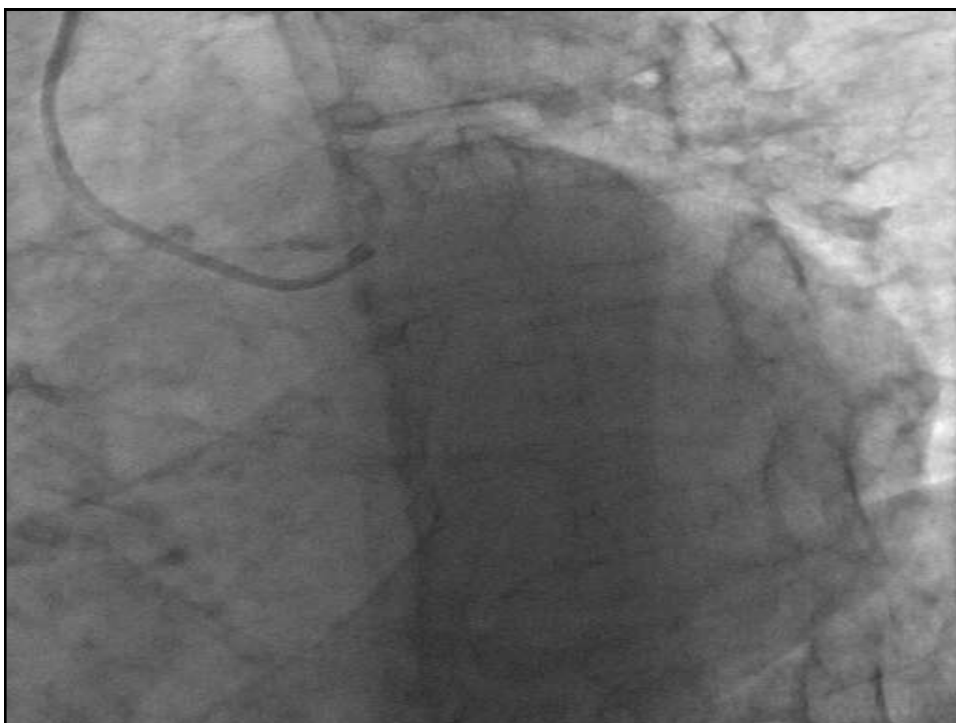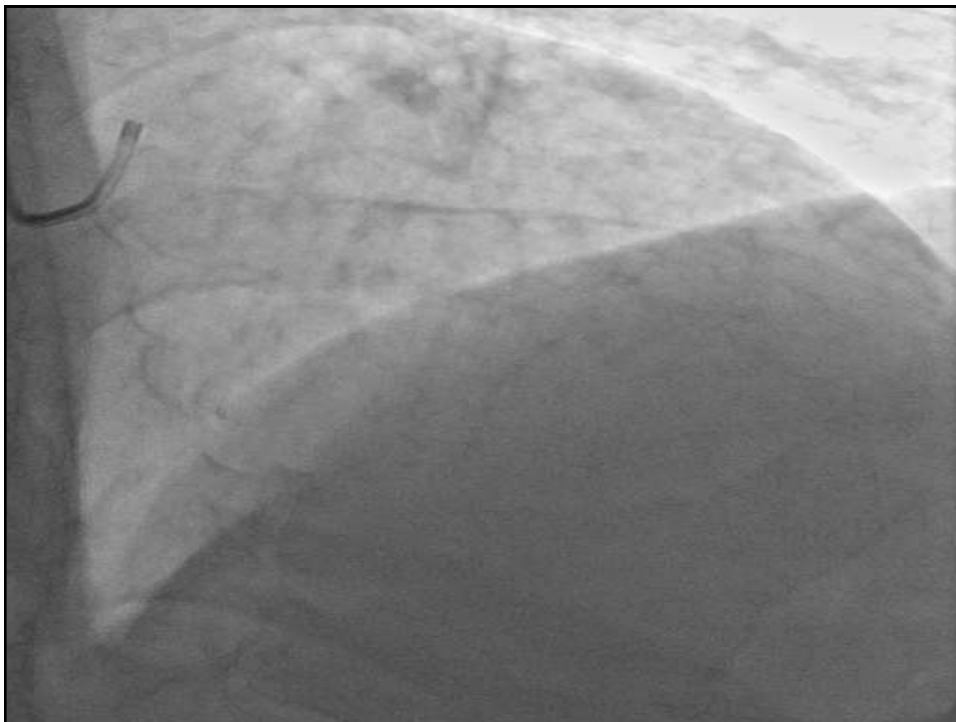
CTO CASE ANTEGRADE

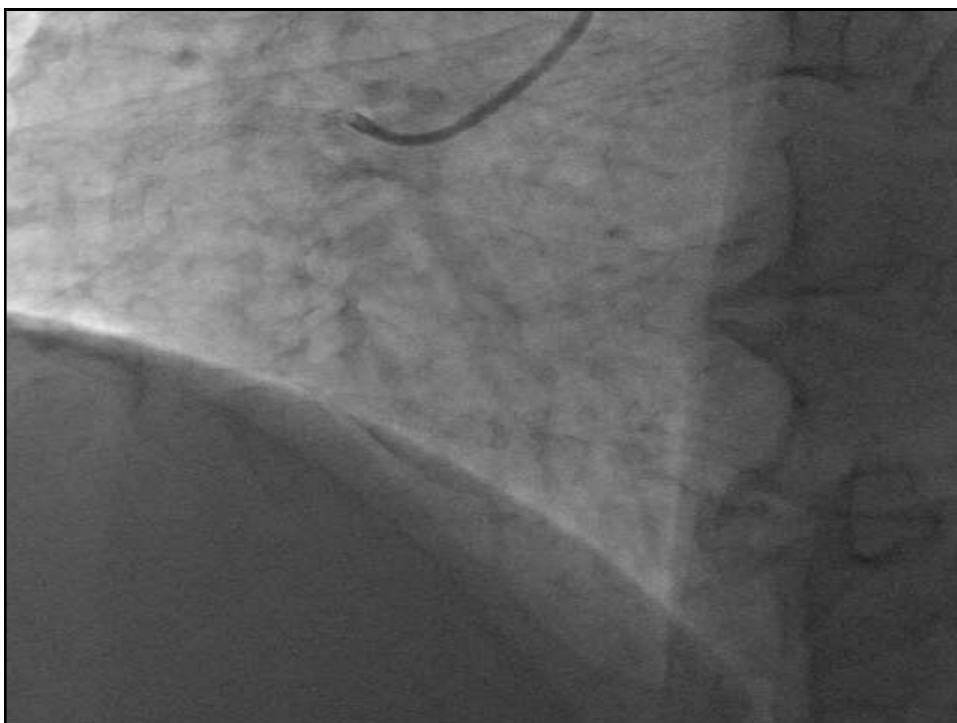
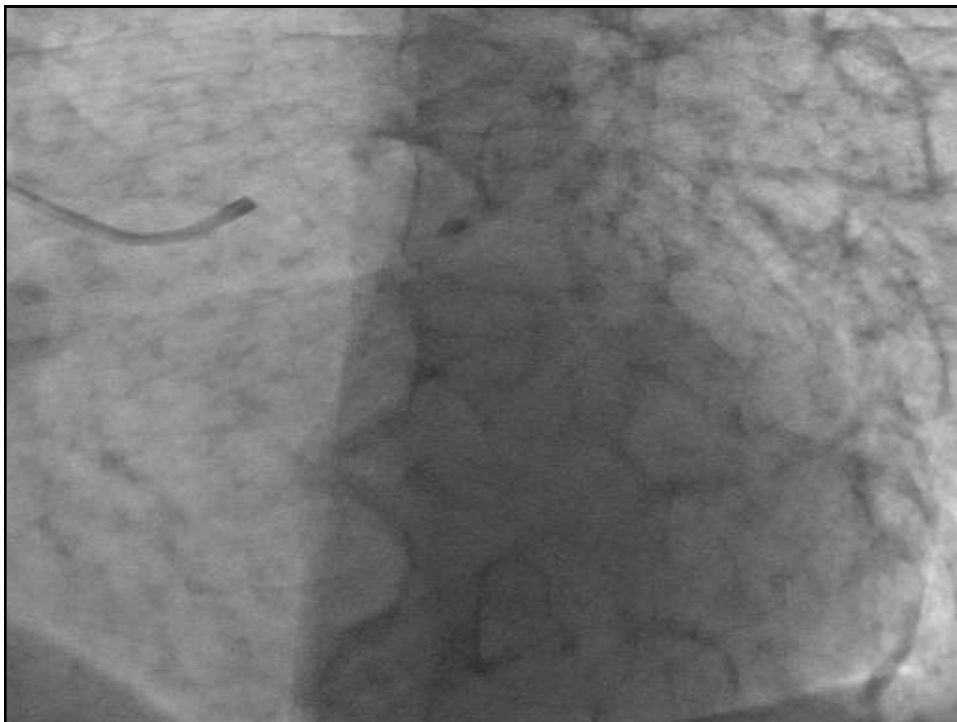AMR ZAKI MD
ALEXANDRIA UNIVERSITY

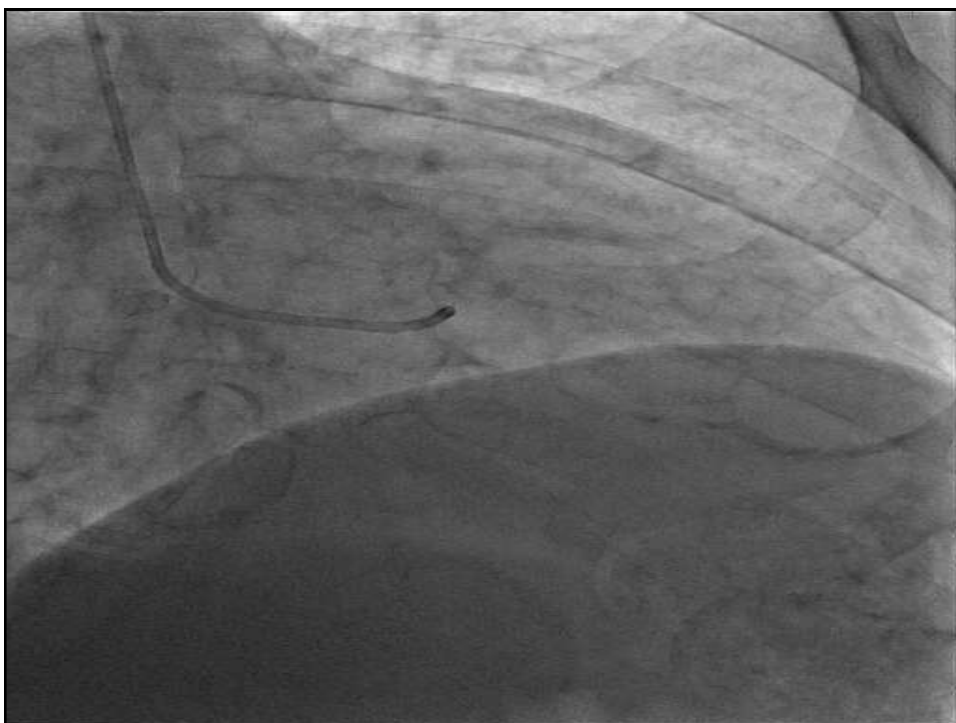
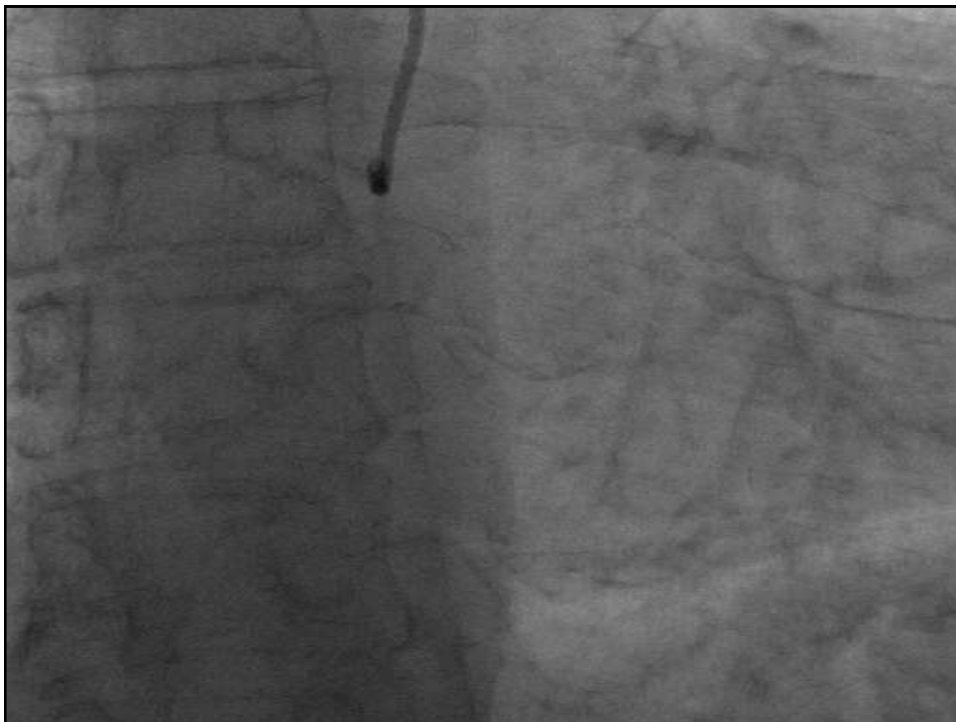- ▶ MALE patient 51 yrs presented with INF STEMI 2015 managed by PPCI DISTAL RCA { FOCAL } PD WAS 80 % PROX RCA 70 % & CTO PROX . LAD. .. PATIENT was scheduled for CABG surgery 3 months later but denied.
- ▶ April 2017, UA RCA was found with CTO distal to STENT EF 40 % DOB ECHO recoverable ant and inf. wall -- denied surgery again & surgeon reluctant .. complex PCI RCA

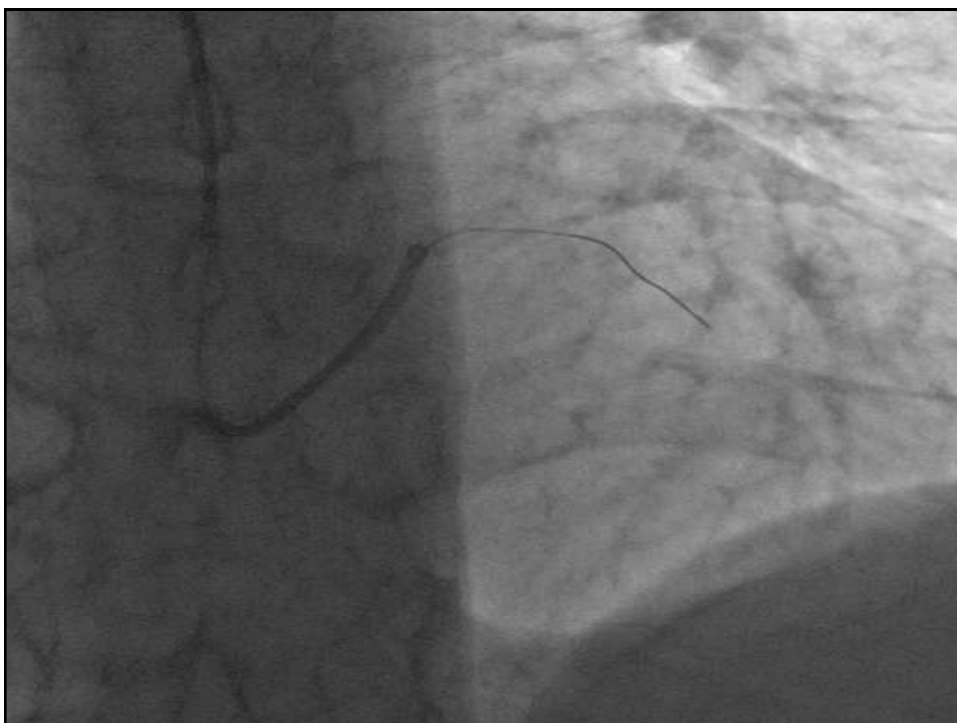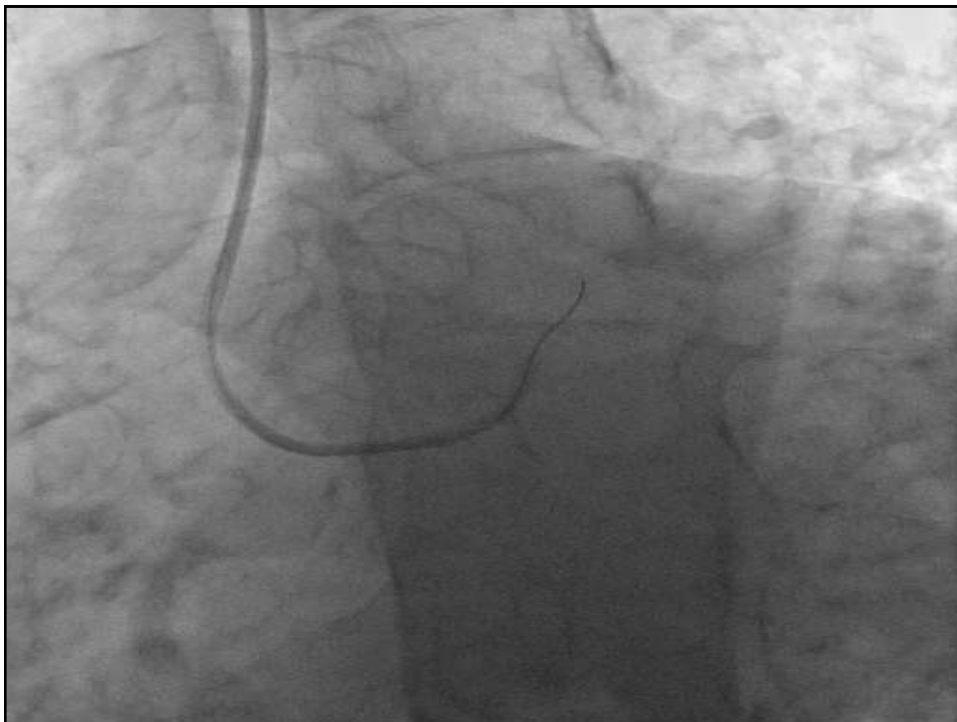
- ▶ RF HTN SMOKER FH of IHD
- ▶ NORMAL renal function .
- ▶ ECHO EF 55% NORMAL regional wall motion.

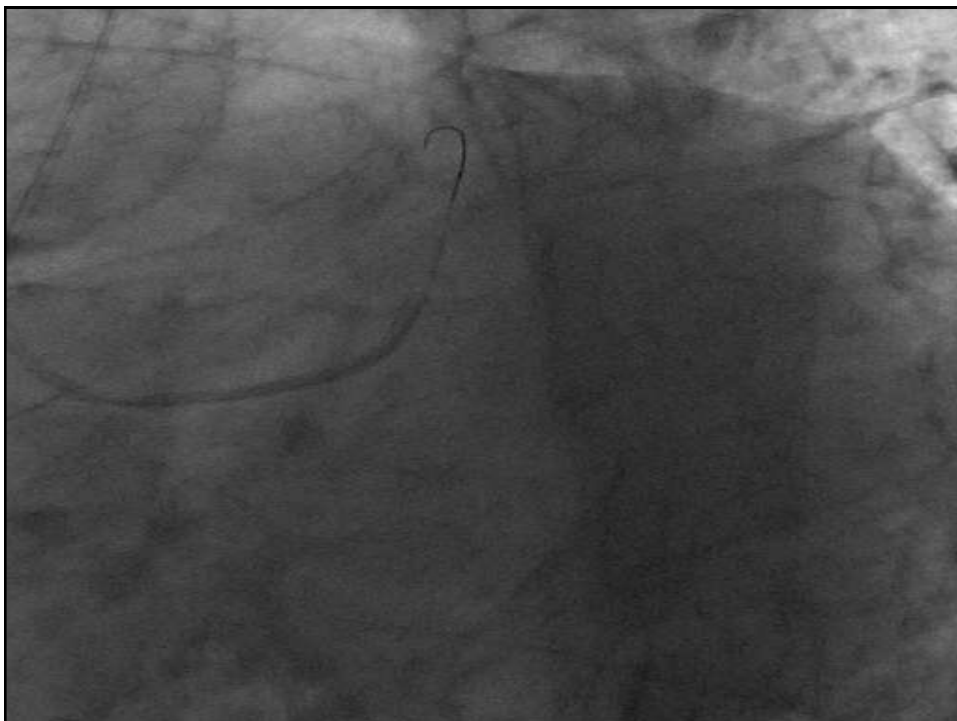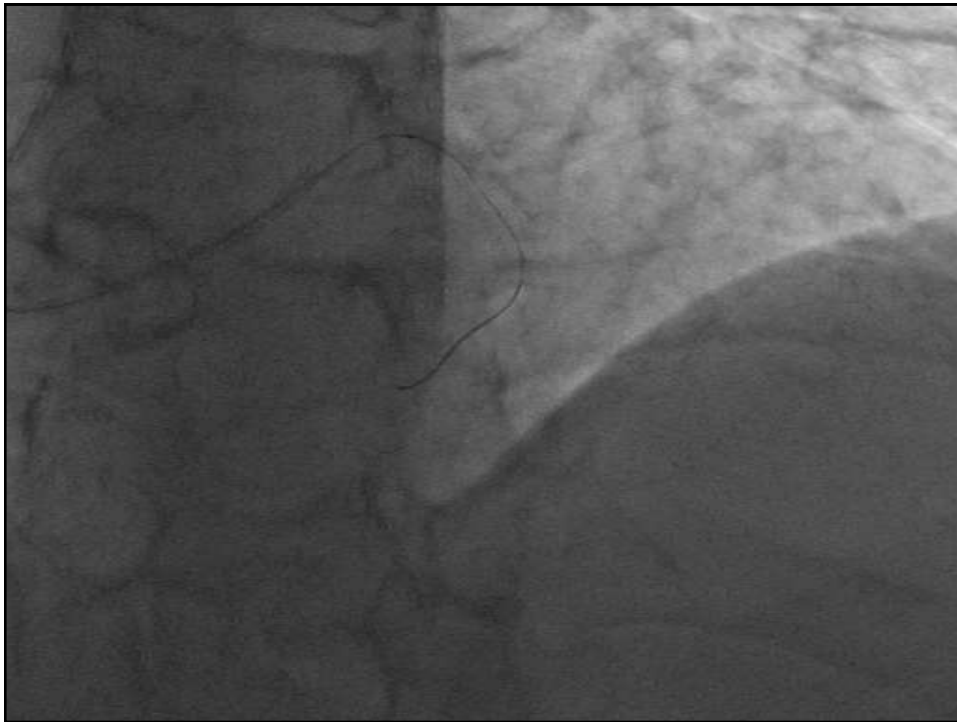


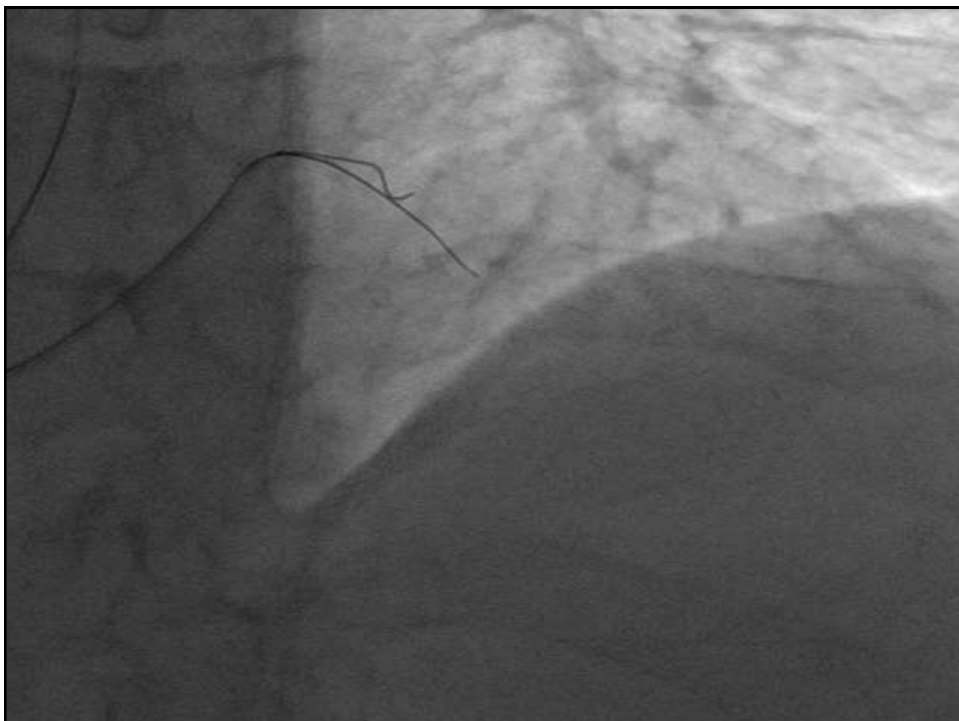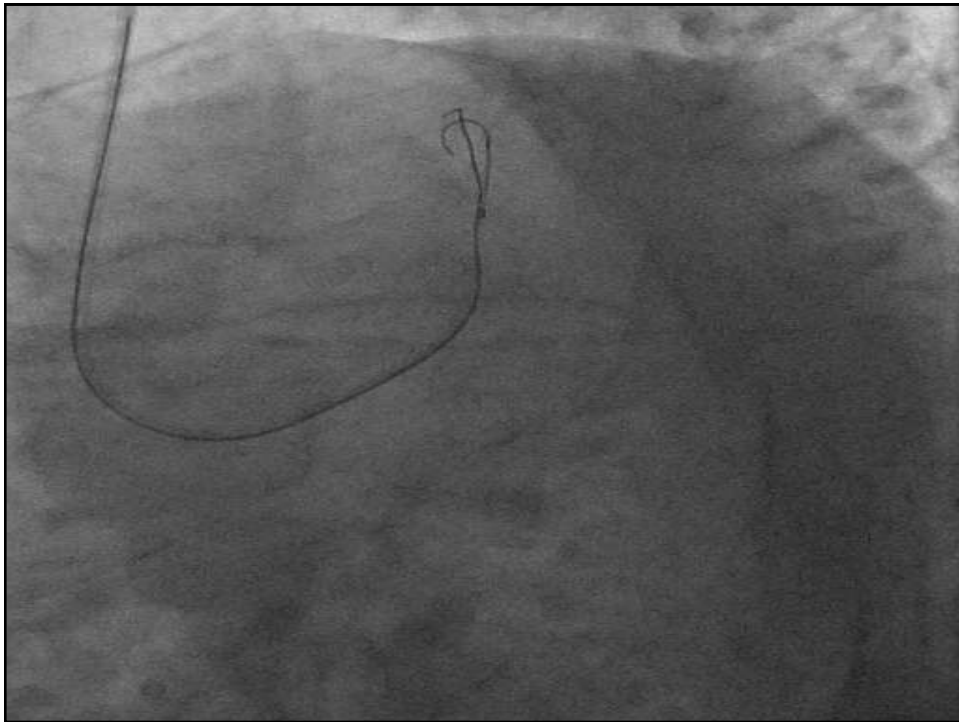


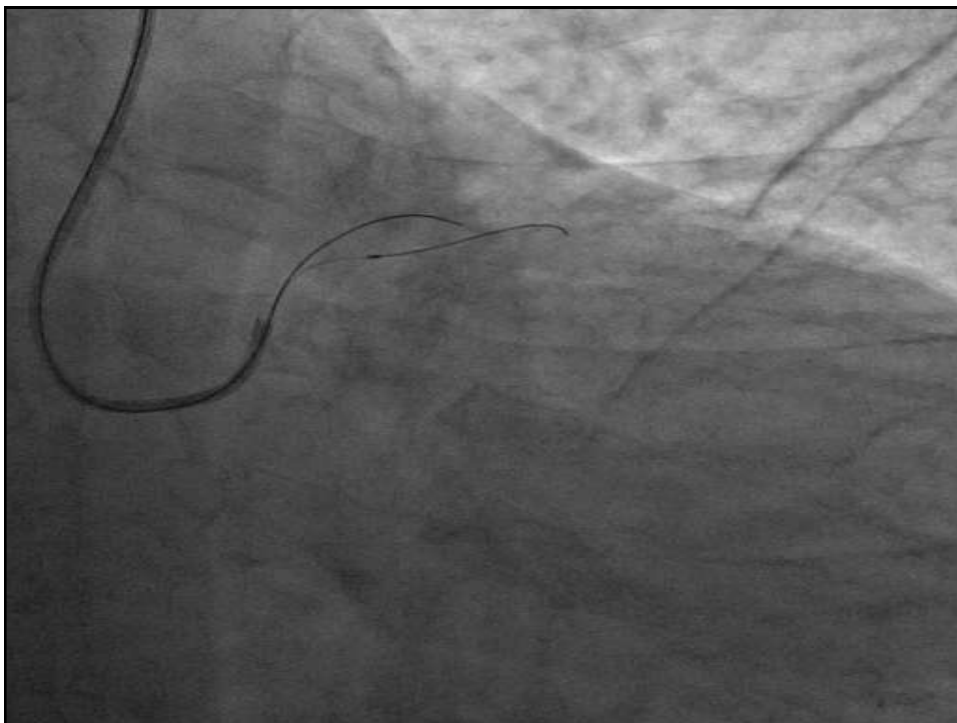
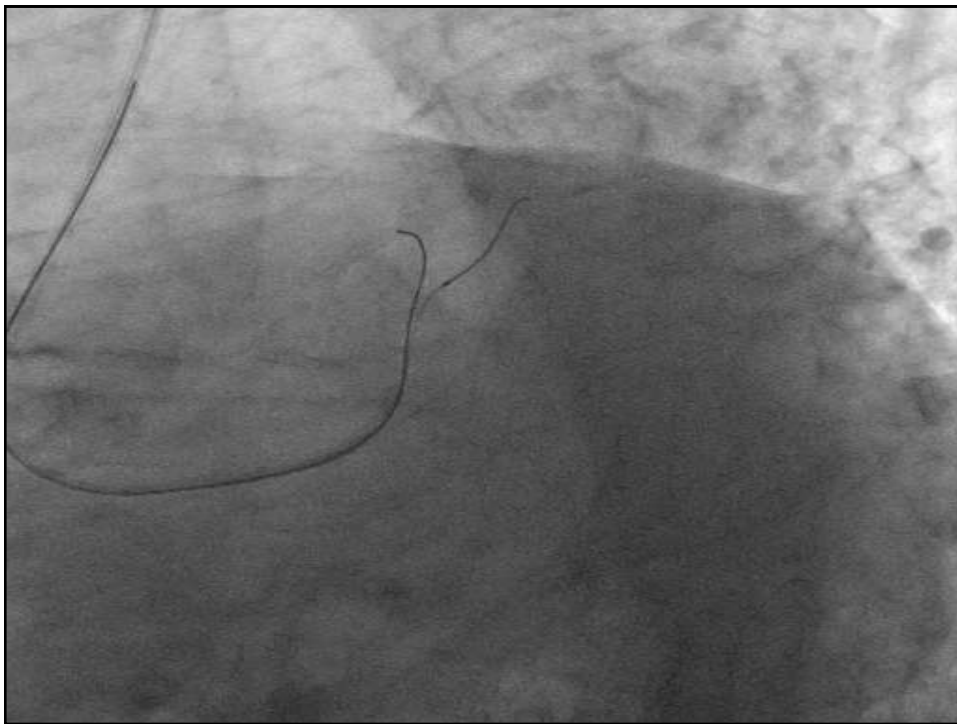


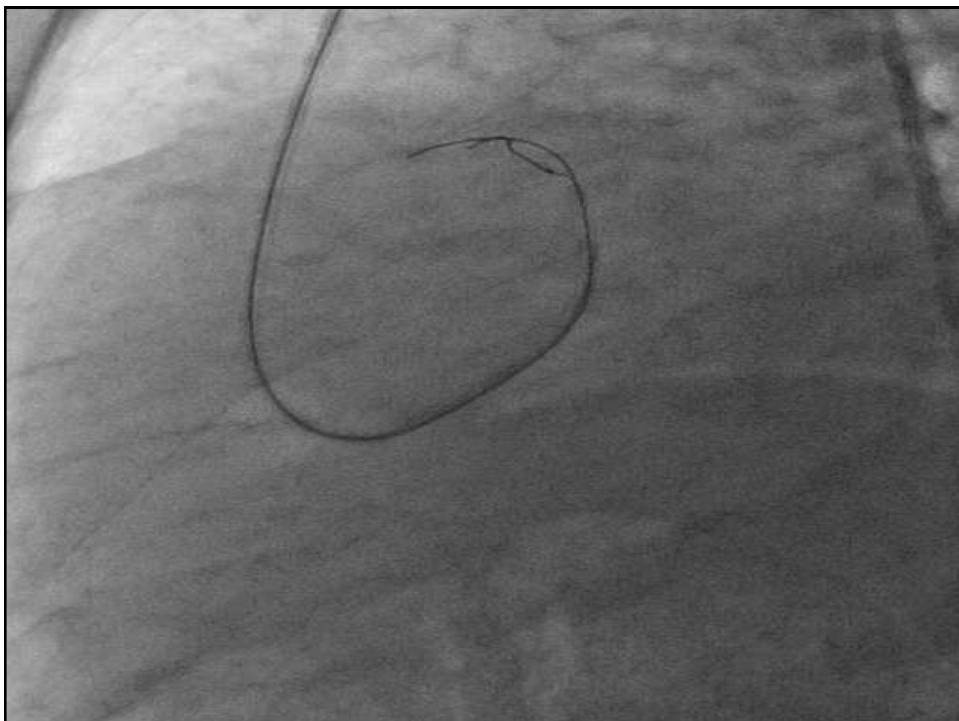
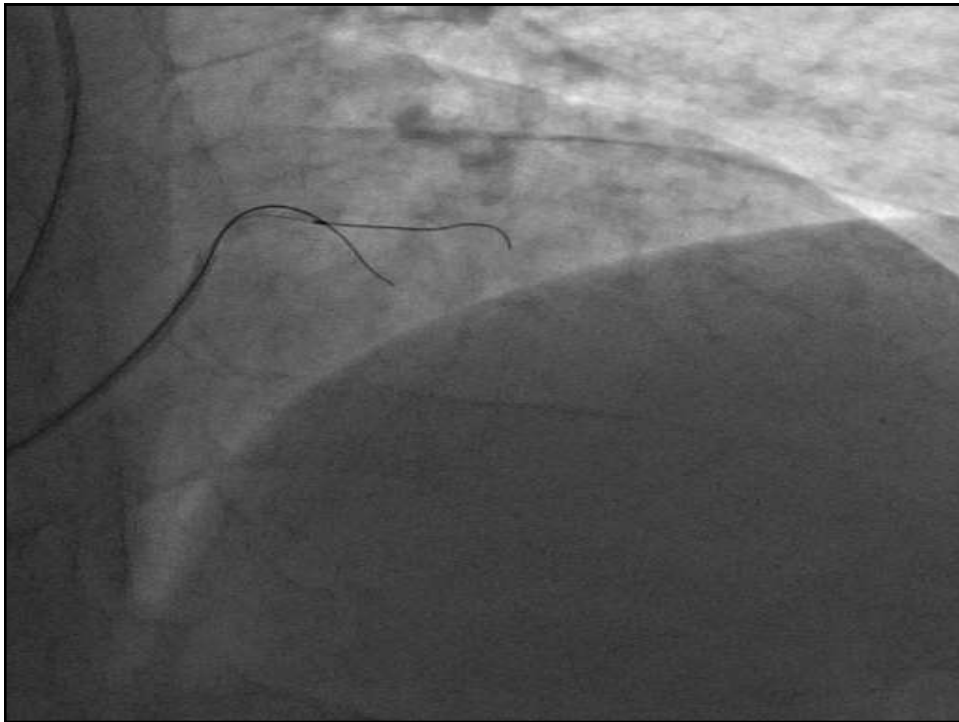






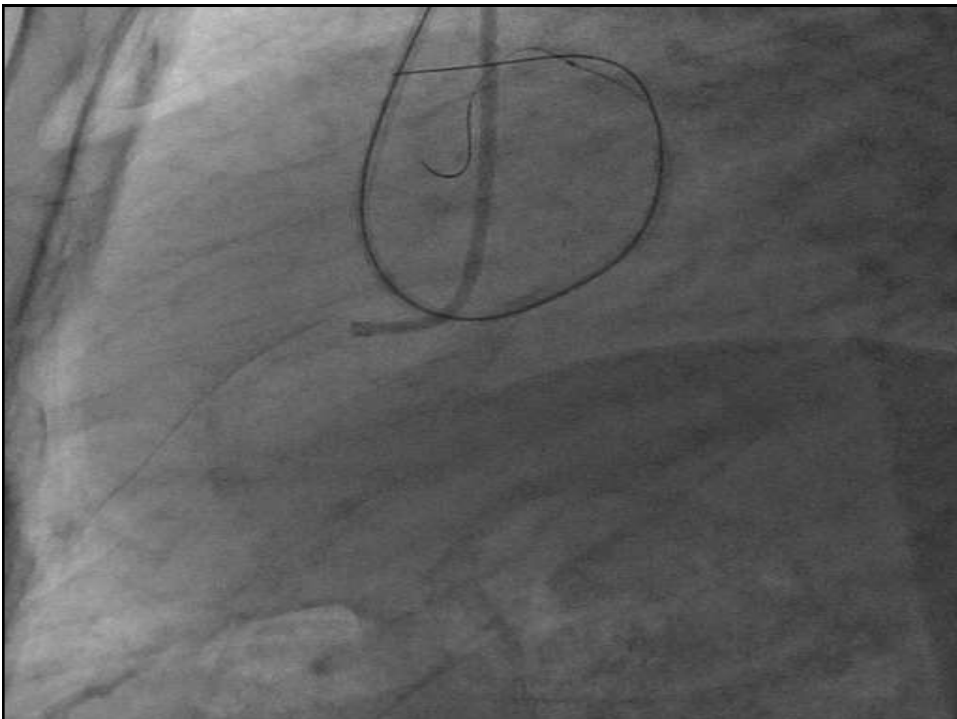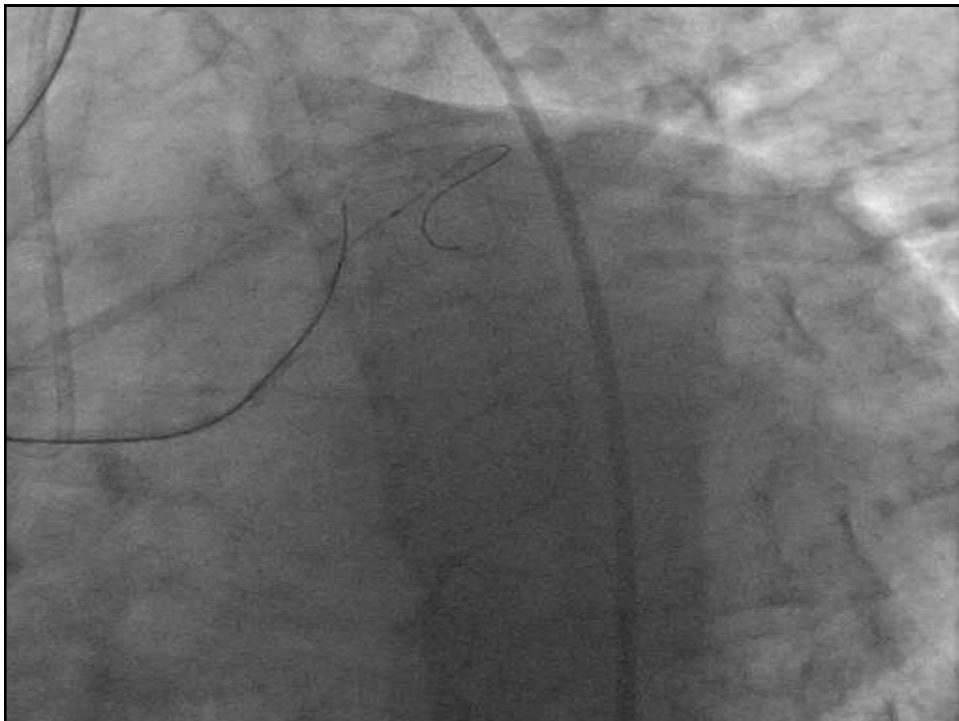
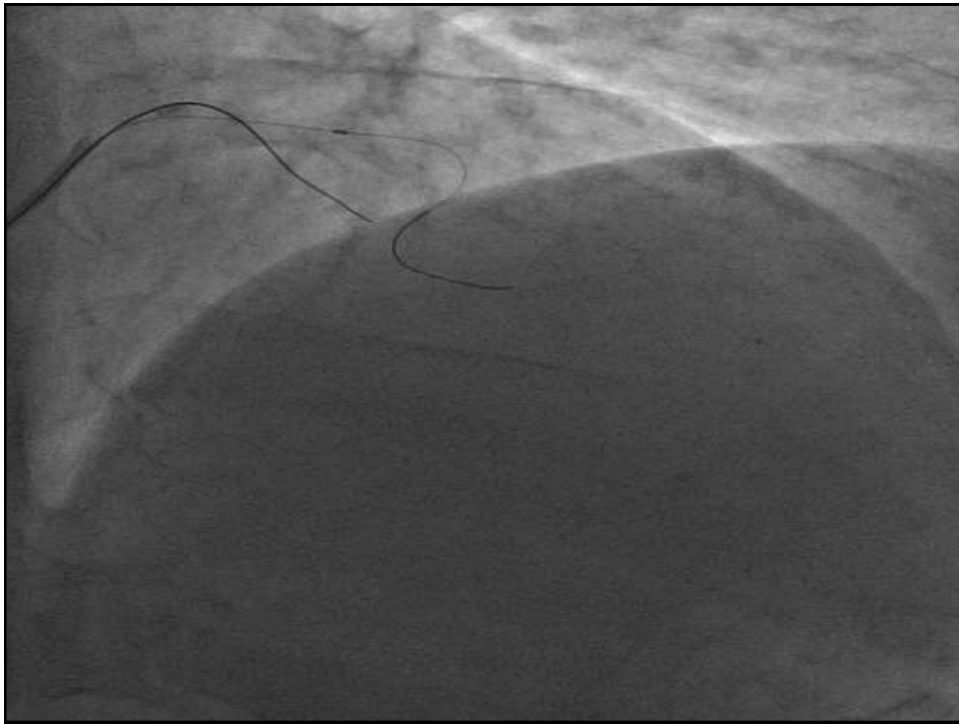


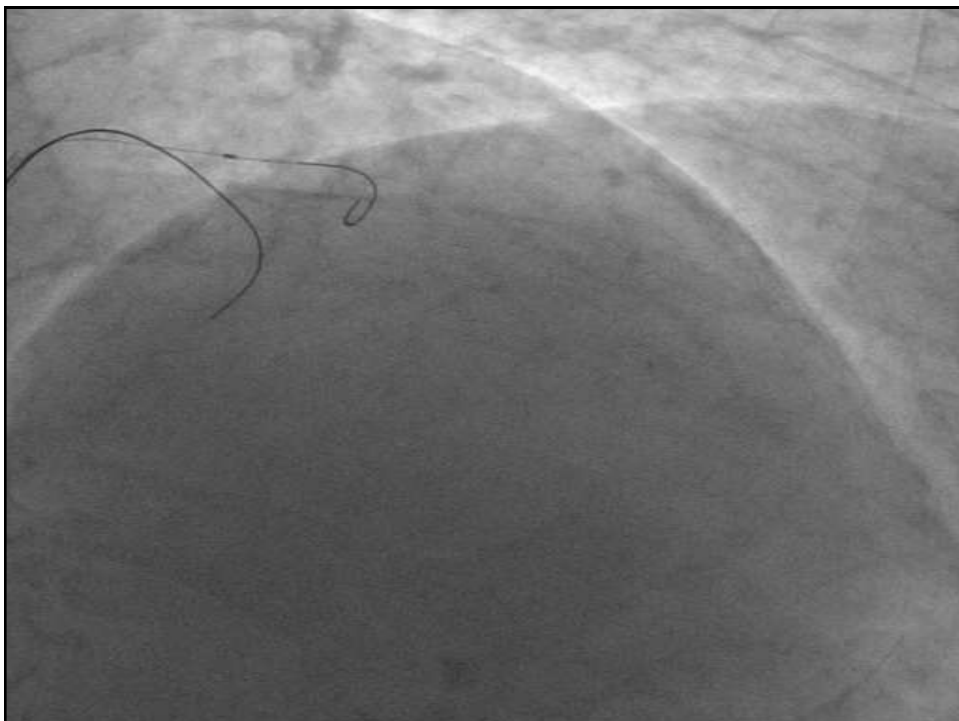
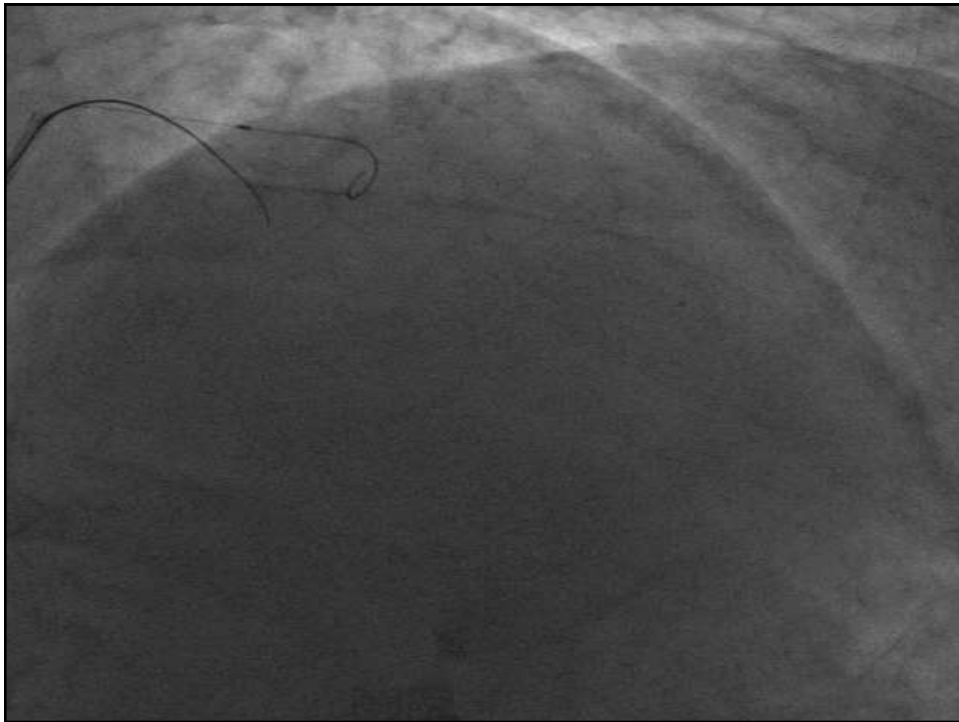


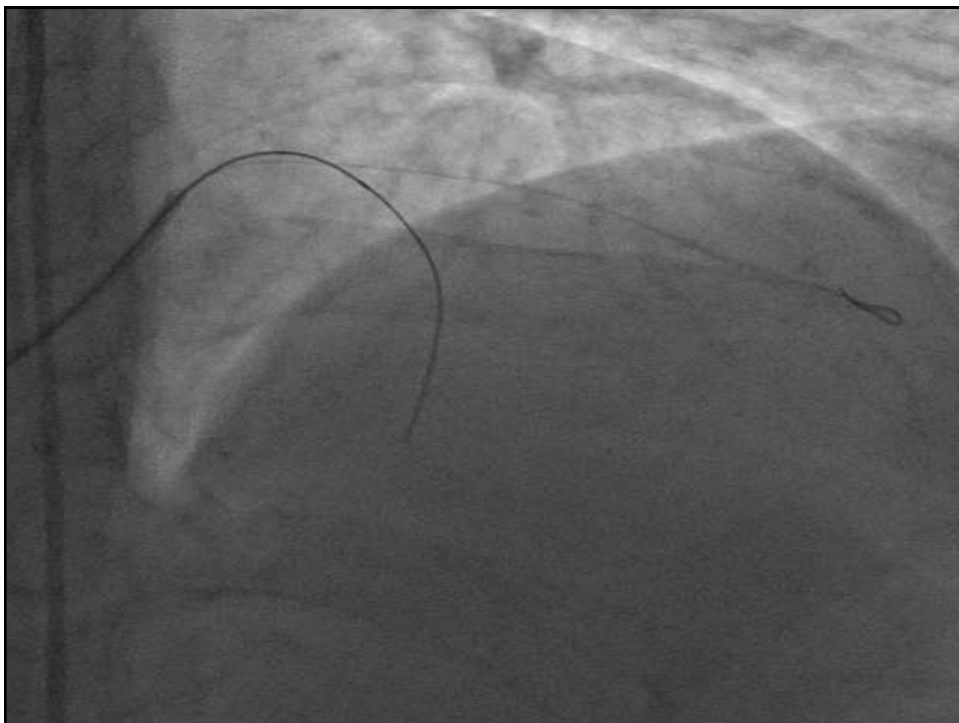
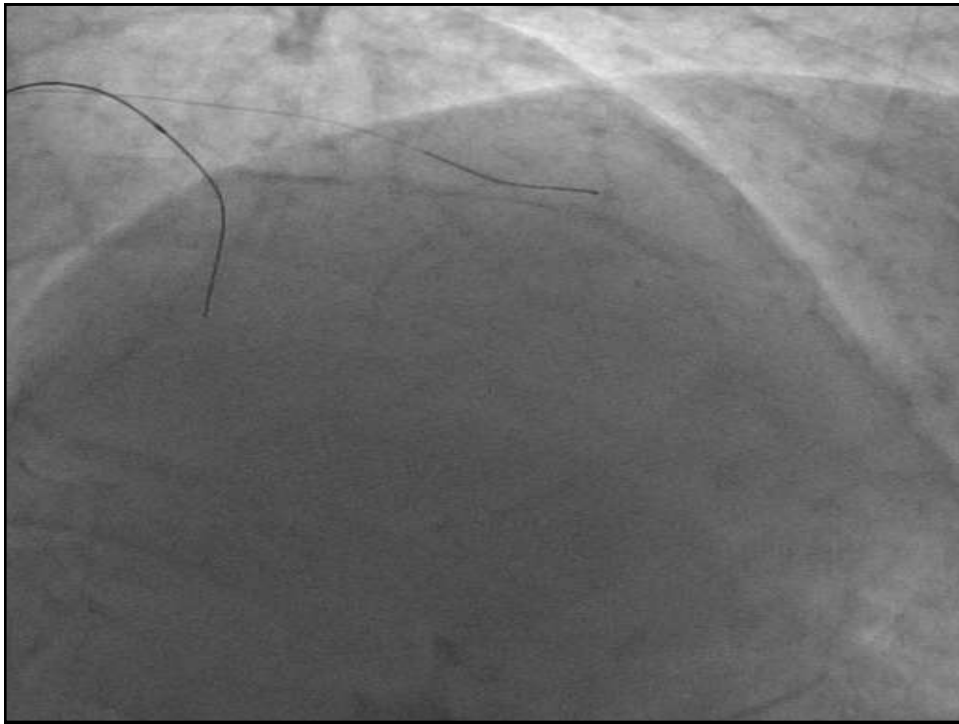


What's Next?

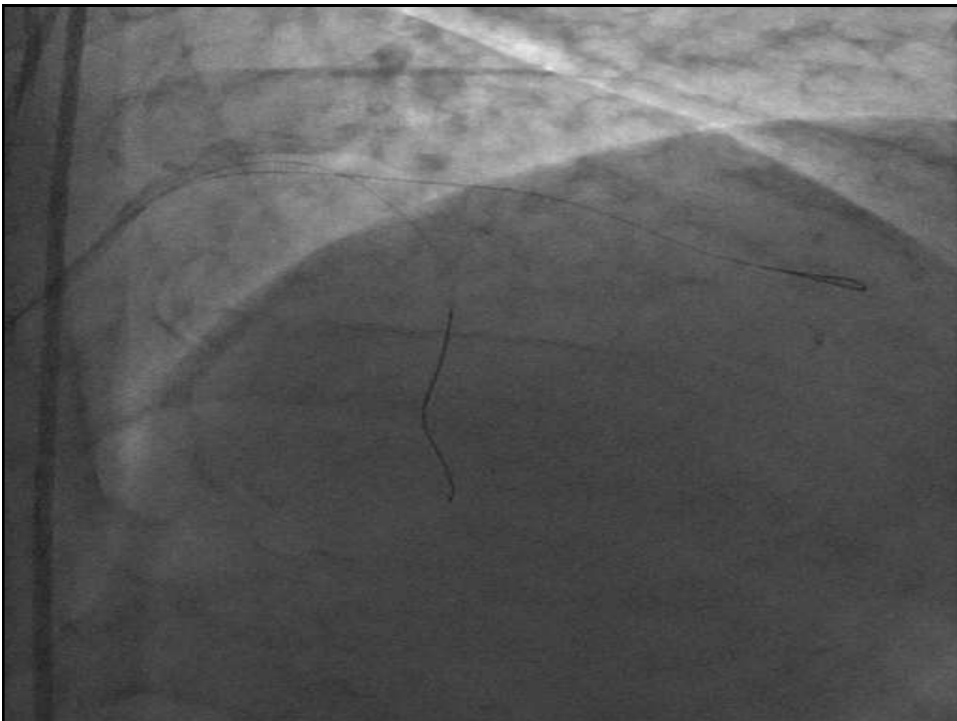


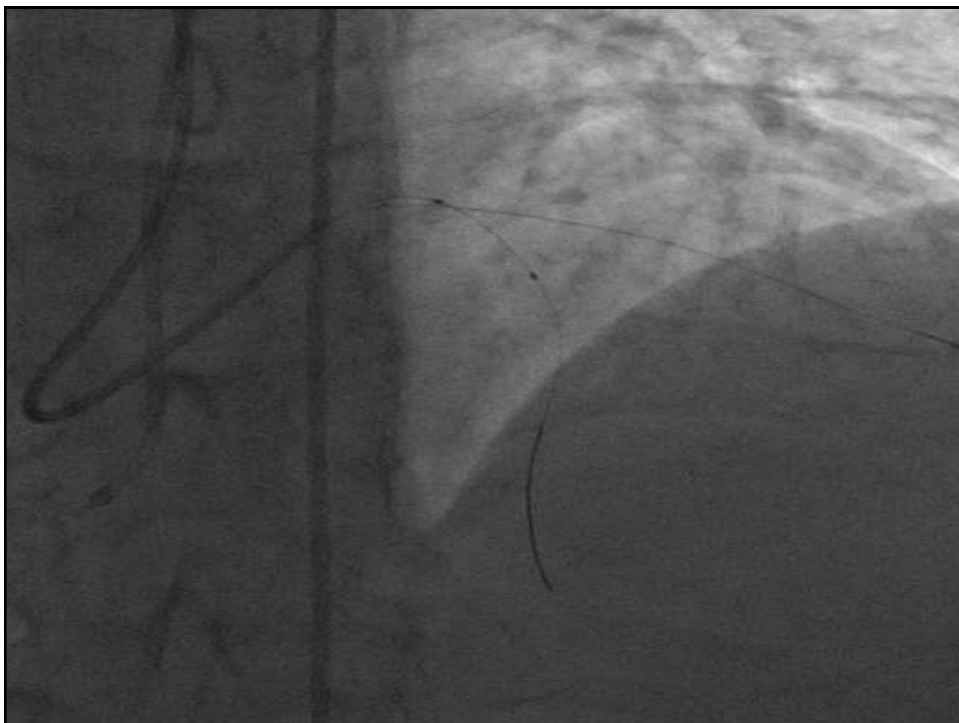
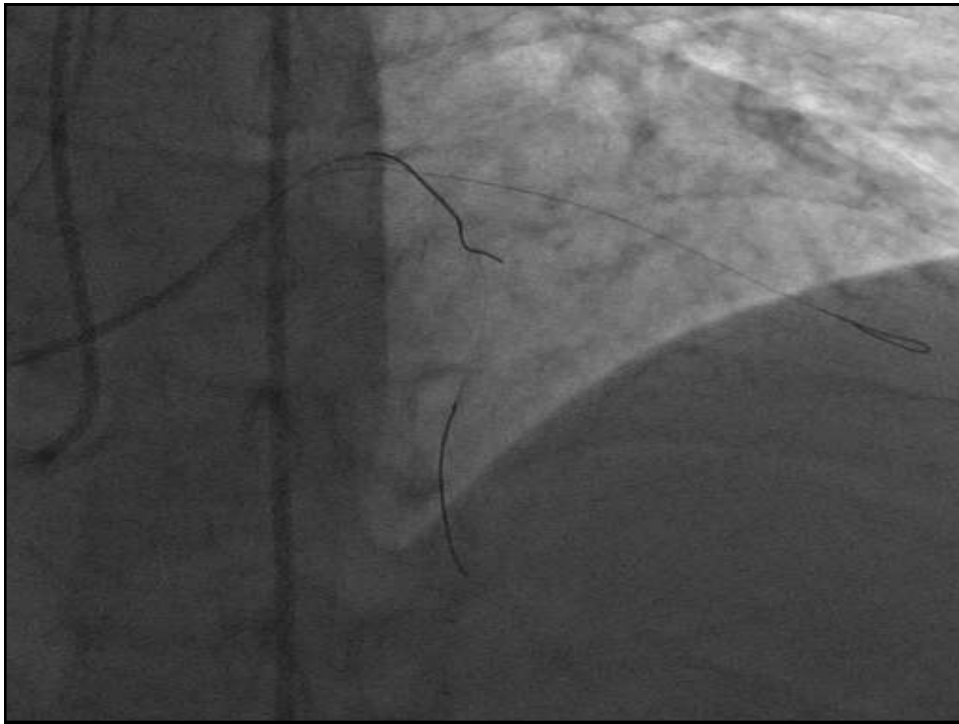


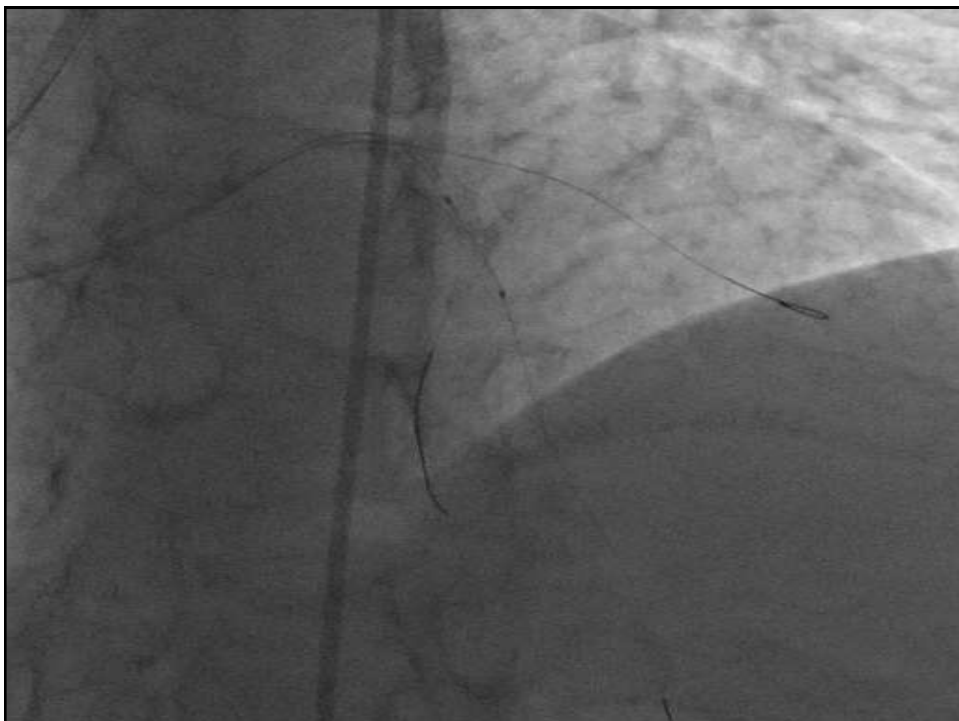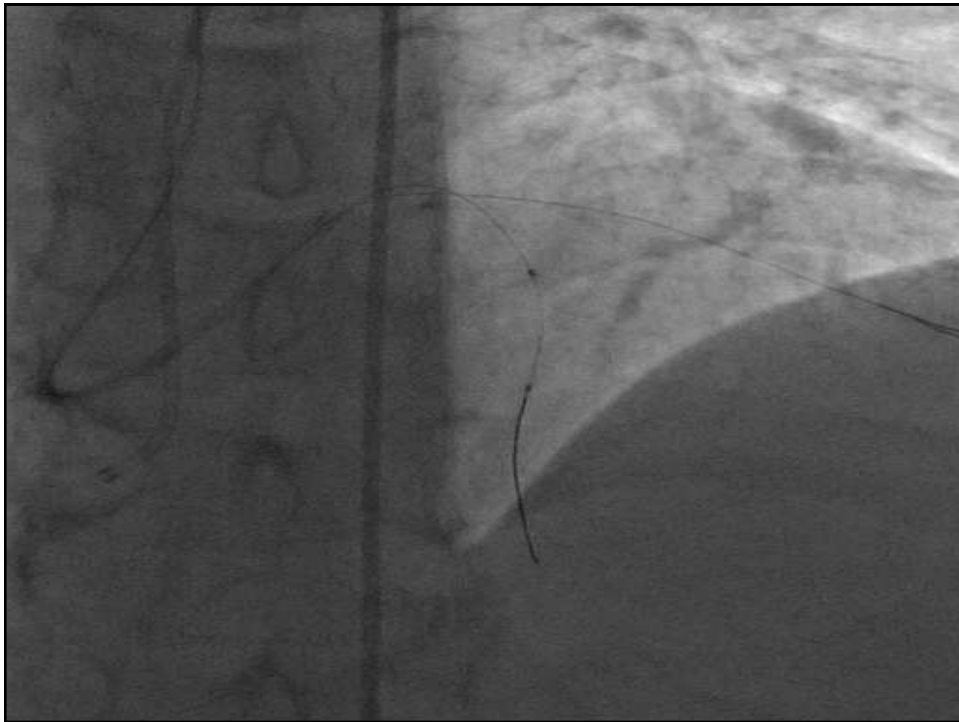


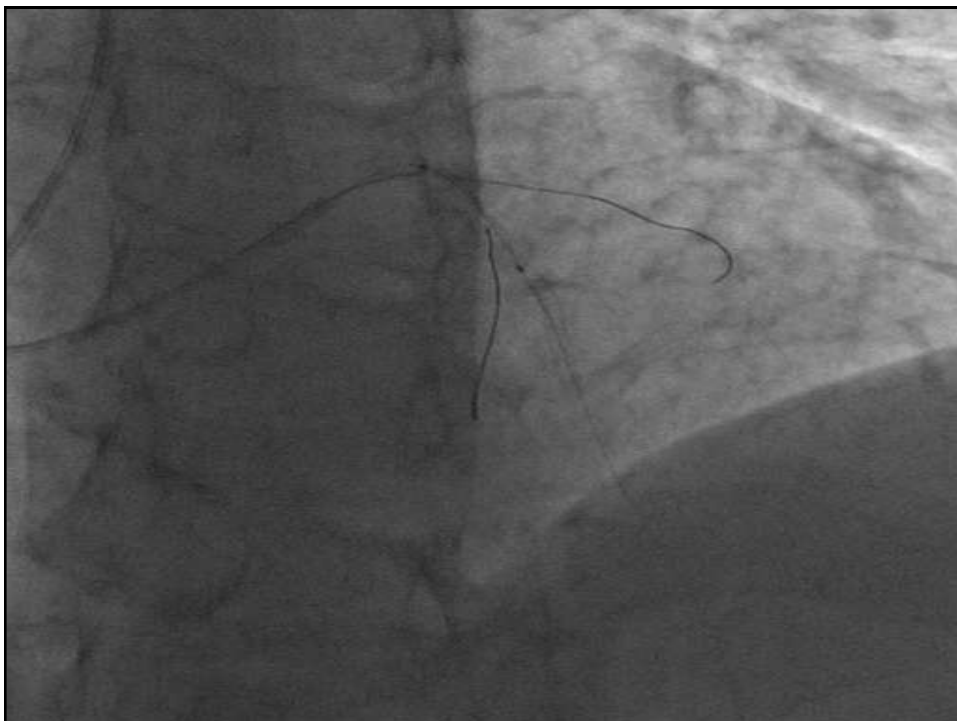
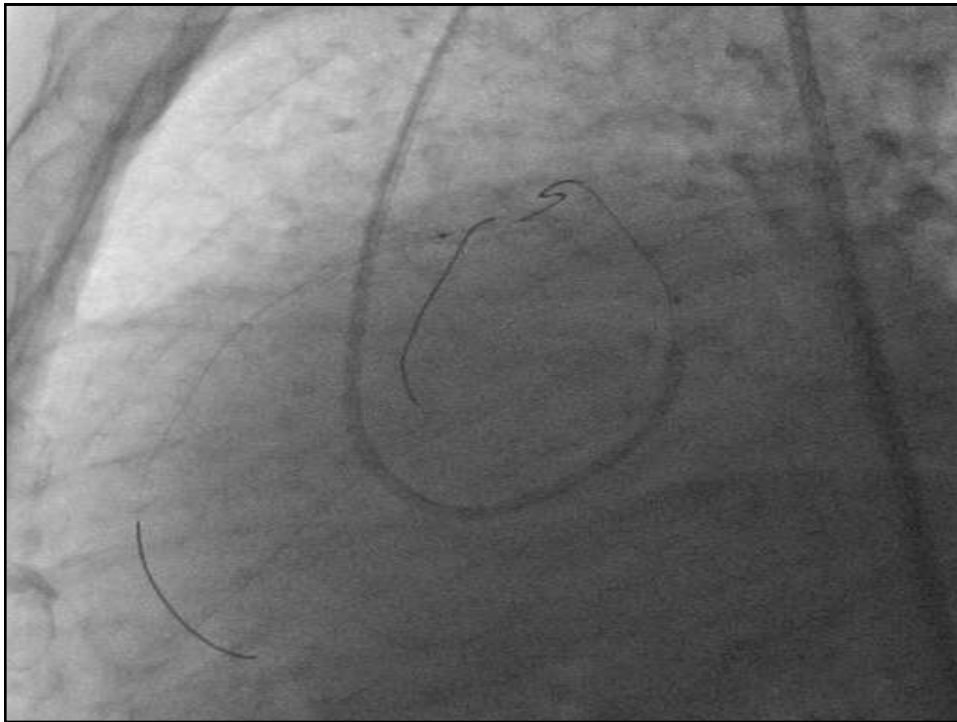


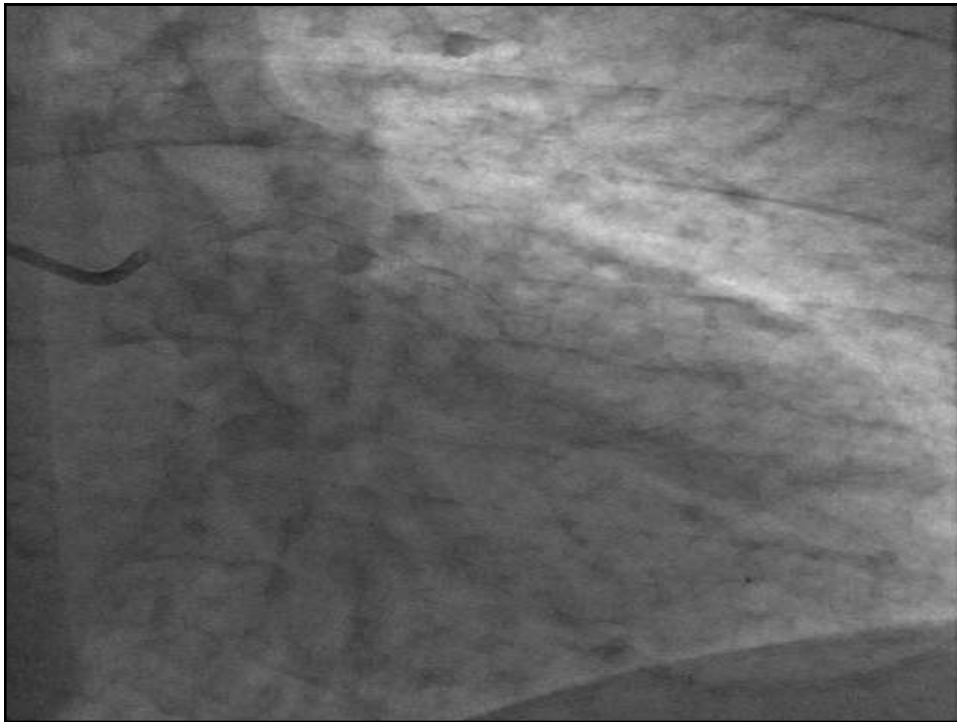
Am I right?











Thank you